Häufige VES/nicht anhaltende VTs –was nun

Peter Ammann

Kantonsspital St. Gallen

Klinisches Potpurri der VES/NSVT

- Symptomatisch (Palpitationen, Schwindel Synkopen, Aufstossen, Dyspnoe, Panik…) und asymptomatisch
- Marker: schweren Erkrankung vs harmlos vs wir wissen es nicht
- Viele Ursachen: Elektrolyststörungen, endokrinologischen Erkrankungen SHD, genetisch bedingt, unklar (idiopatisch)
- Mechanismus: Reentry, getriggerte Aktivität und abnorme Automatie
- Medikamentöse Behandlung: schwierig, hat oft NW
- Dokumentation oft ungenügend (12 Ableitung)

Lieber Peter
Der Patient eldet sich immer wieder wegen AZ-Verschlechterung….kardial komepnsiert, normale systolische Funktion.
Sind das VES oder SVEs mit aberrierender Leitung..bin etwas unsicher.
Hat bereits seit Jahren einen BB. Langzeit-EKG läuft
Mit liebem Gruss und immer dankbar

85 jähriger Mann

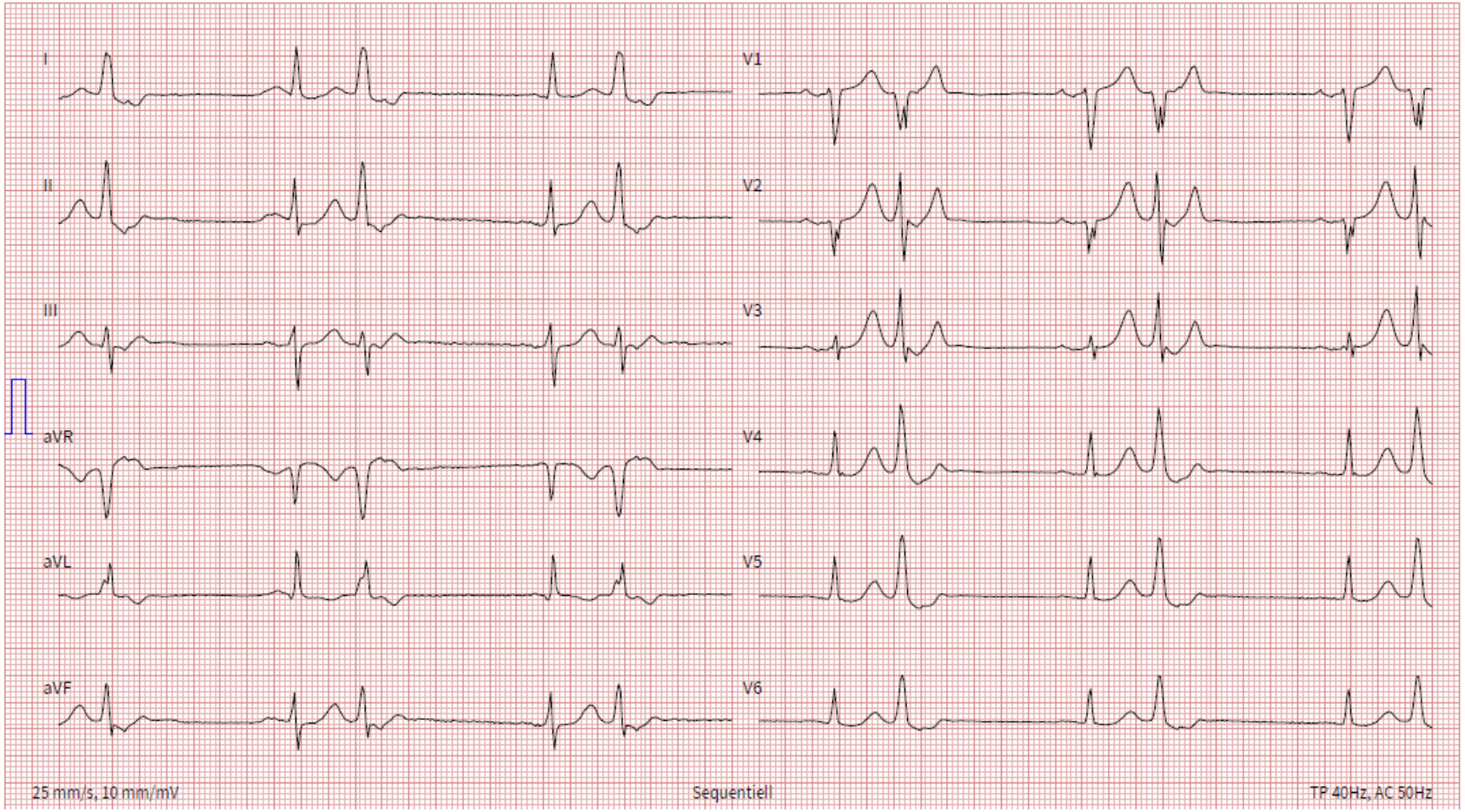

Sind VES gefährlich?

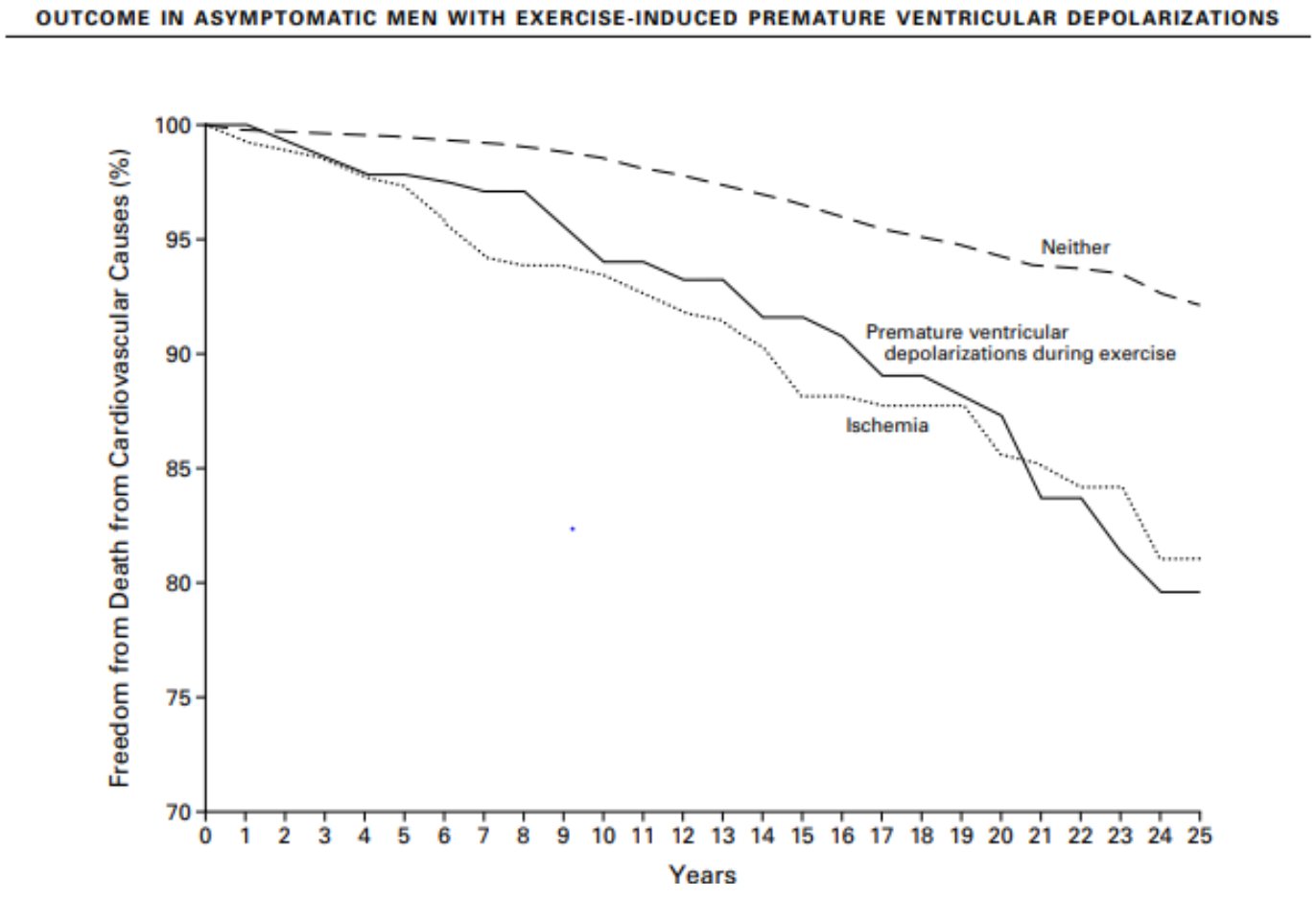

Paris Prospective Study I Jouven et al NEJM 2000

VES und HI?

First Evidence of Premature Ventricular Complex-Induced Cardiomyopathy: A Potentially Reversible Cause of Heart Failure

SUMEET S. CHUGH, M.D., WIN-K. SHEN, M.D., DAVID M. LURIA, M.D., and HUGH C. SMITH, M.D.

From the Cardiovascular Division, Department of Internal Medicine, Mayo Clinic and Mayo Foundation, Rochester, Minnesota

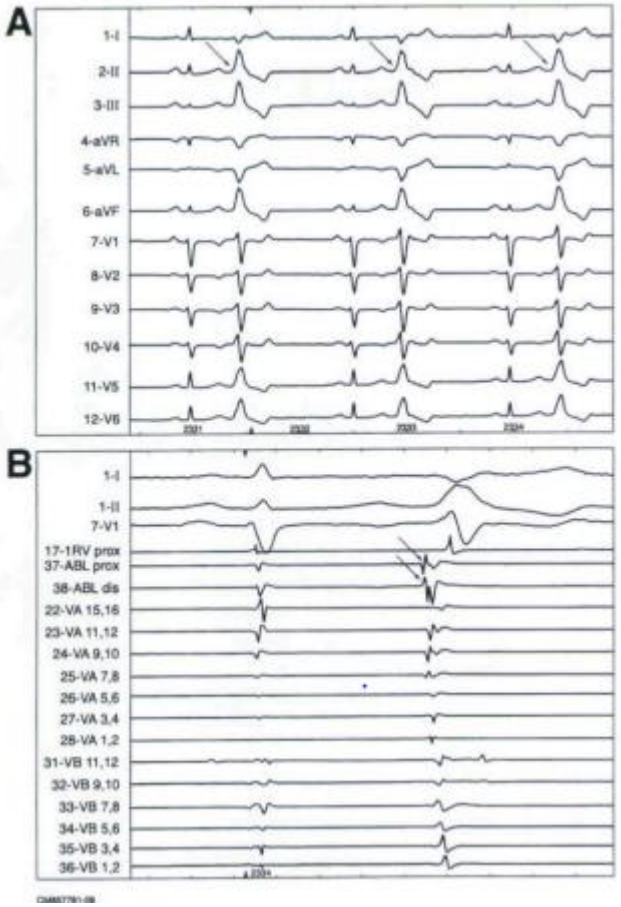

26 yrs old patient LVEF 43%
25-56000 PVC/24h

RVOT Ablation

J Cardiovasc Electrophy 2000

4yr FU in pts with PVC burden

- Weak but significant association of PVC burden and LVEF ⬇

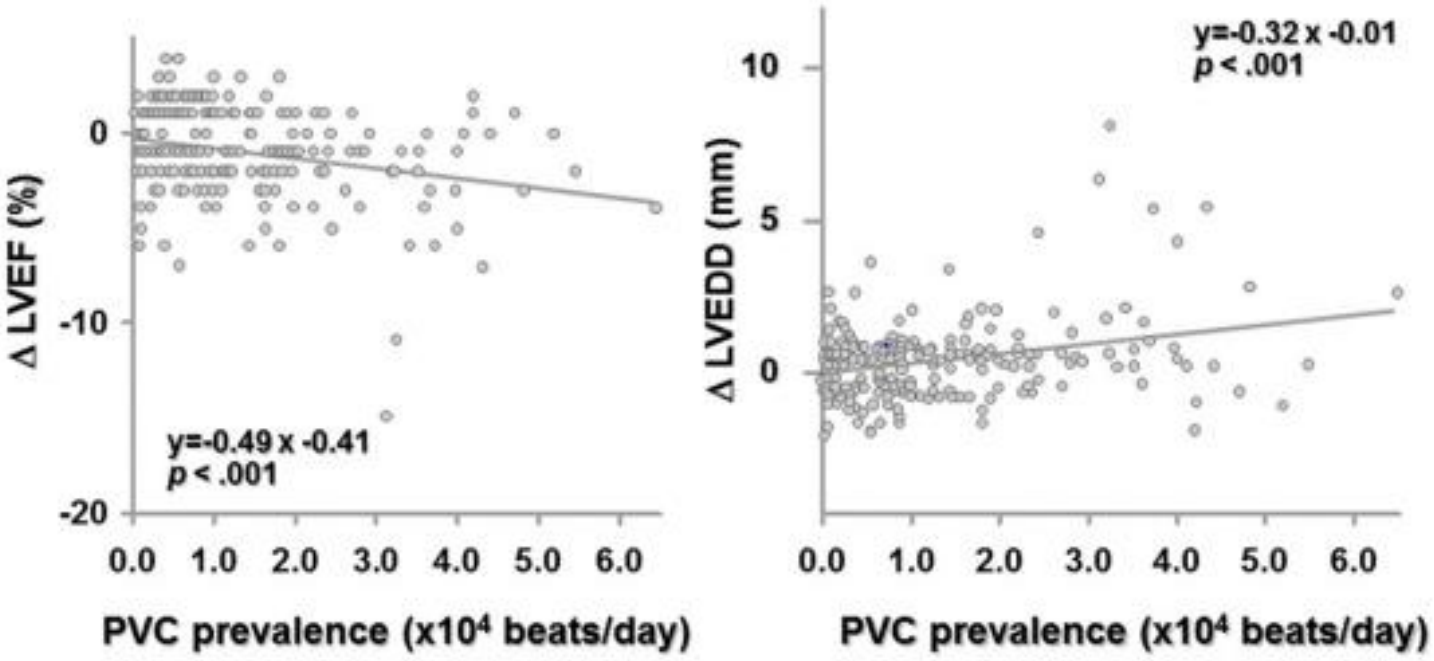

Lee et al Circ Arrythmia 2012

Left Ventricular Dysfunction in Outpatients with Frequent Ventricular Premature Complexes

Kyoung-Min Park, MD[1]; Sung Il Im, MD[1]; Sung Ho Lee, MD[1]; Hye Bin Gwag, MD[1]; Youngjun Park, MD[1]; Seung-Jung Park, MD[1]; June Soo Kim, MD[1]; Young Keun On, MD[1]

[1]Division of Cardiology, Department of Internal Medicine, Samsung Medical Center, Sungkyunkwan
Seoul, Republic of Korea

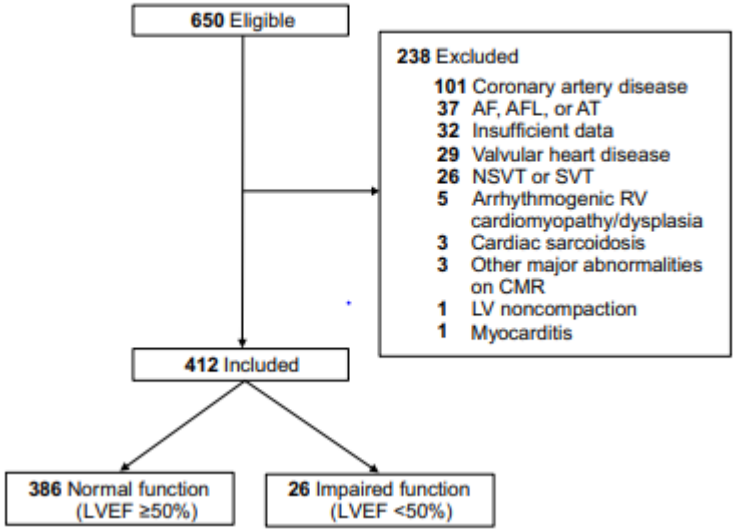

Mean VPC burden (LVEF> 50 PVC 11 ±10% vs <50, 14,4 ± 13,3 p=ns

LV< 50

more men,
no typical PVC related symptoms,
mean QRS duration **157 ms vs 139 m**s p< 0.01

Texas Heart Institute Journal 2022

Diagnosis and quantification of frequent PVCs

- Symptoms: palpitations, presyncope, or decreased effort tolerance
- Physical exam: often normal, premature beats may be appreciated
- ECG: to determine PVC morphology
- Holter monitoring: to quantify PVC burden

↓

Echocardiography

- To assess for LVEF and LV structural abnormalities

↓

Further cardiac evaluation

- MRI, stress imaging and coronary angiography should be performed where indicated to exclude structural etiologies for frequent PVCs
- Workup to exclude cardiomyopathies due to other causes, such as drugs and endocrinopathies

↓

Suppression of PVCs

- If PVC-induced cardiomyopathy is presumed, physicians may proceed with a therapeutic medical trial or catheter ablation

↓

Follow-up

- Follow-up of between 3 and 12 months with repeat Holter monitoring and echocardiography

12 Ableitungs Holter!

PVC > 140 ms vs PVC < 140 ms
Some evidence LV worse than RV

Lee Circ Arrythmia 2012

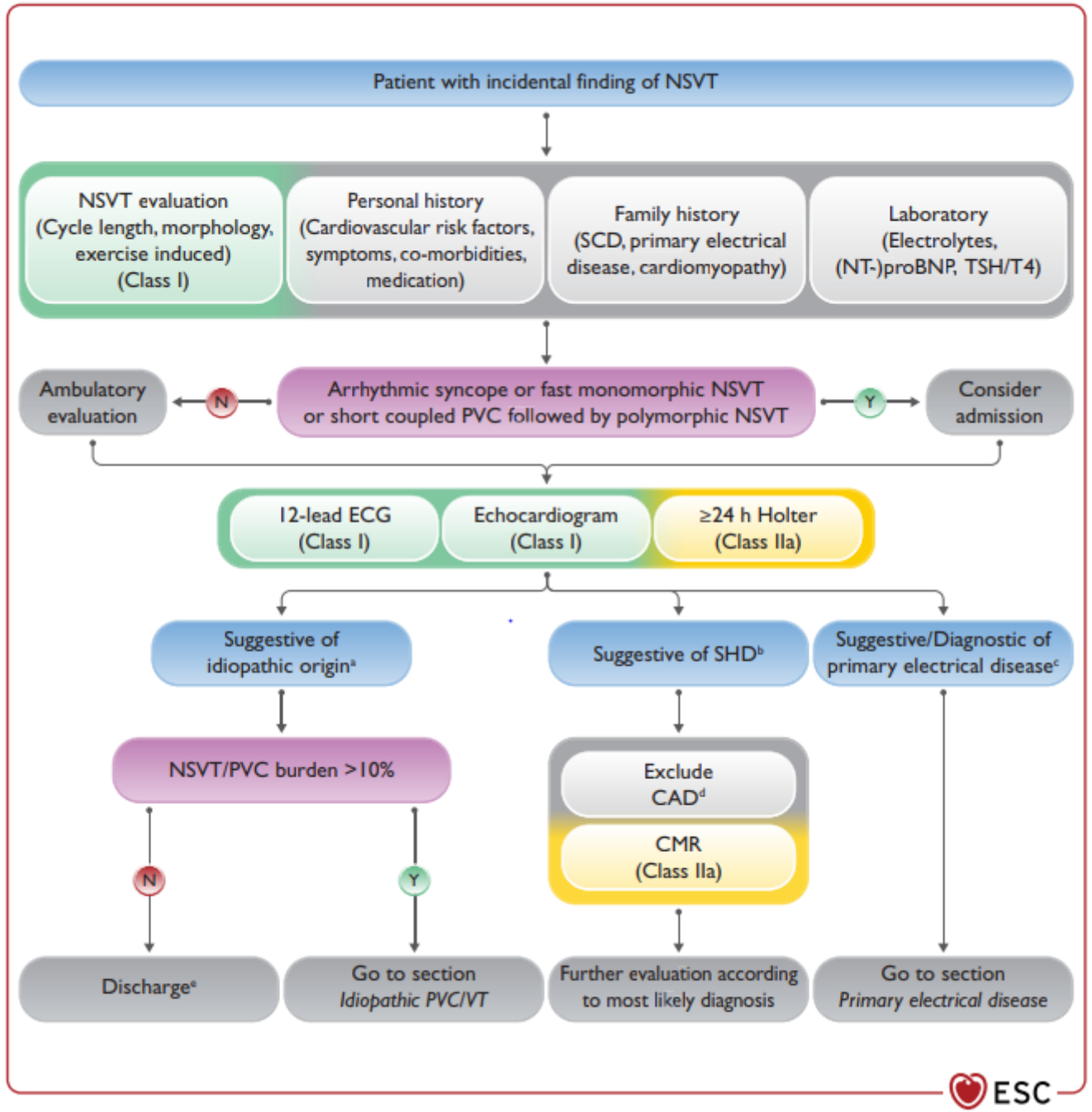
Patient with incidental finding of NSVT
NSVT evaluation (Cycle length, morphology, exercise induced) (Class I)
Personal history (Cardiovascular risk factors, symptoms, co-morbidities, medication)
Family history (SCD, primary electrical disease, cardiomyopathy)
Laboratory (Electrolytes, (NT-)proBNP, TSH/T4)
Ambulatory evaluation
N
Arrhythmic syncope or fast monomorphic NSVT or short coupled PVC followed by polymorphic NSVT
Y
Consider admission
12-lead ECG (Class I)
Echocardiogram (Class I)
≥24 h Holter (Class IIa)
Suggestive of idiopathic origin[a]
Suggestive of SHD[b]
Suggestive/Diagnostic of primary electrical disease[c]
NSVT/PVC burden >10%
Exclude CAD[d]
CMR (Class IIa)
N
Y
Discharge[e]
Go to section Idiopathic PVC/VT
Further evaluation according to most likely diagnosis
Go to section Primary electrical disease
ESC

PVC locatization for beginners

1. RBBB : left ventricle
2. LBBB : right ventricle/septum
3. Inf axis (II,III,avF pos): sup.aspect of ventricle
4. Sup axis (II,III,avG neg): inf aspect of ventricle
5. QS V6: near apex
6. R/S >1 (V6) base,outflow/annuli
7. R/S < 1 (V6) middle ventricle (PM/fascicular)

8. Idiopatic outflow:
    1. no S in I/RBBP R trans < V 3 = LVOT
    2. S in I, R trans > V3 = RVOT

for experts Yamada 2019 JCE

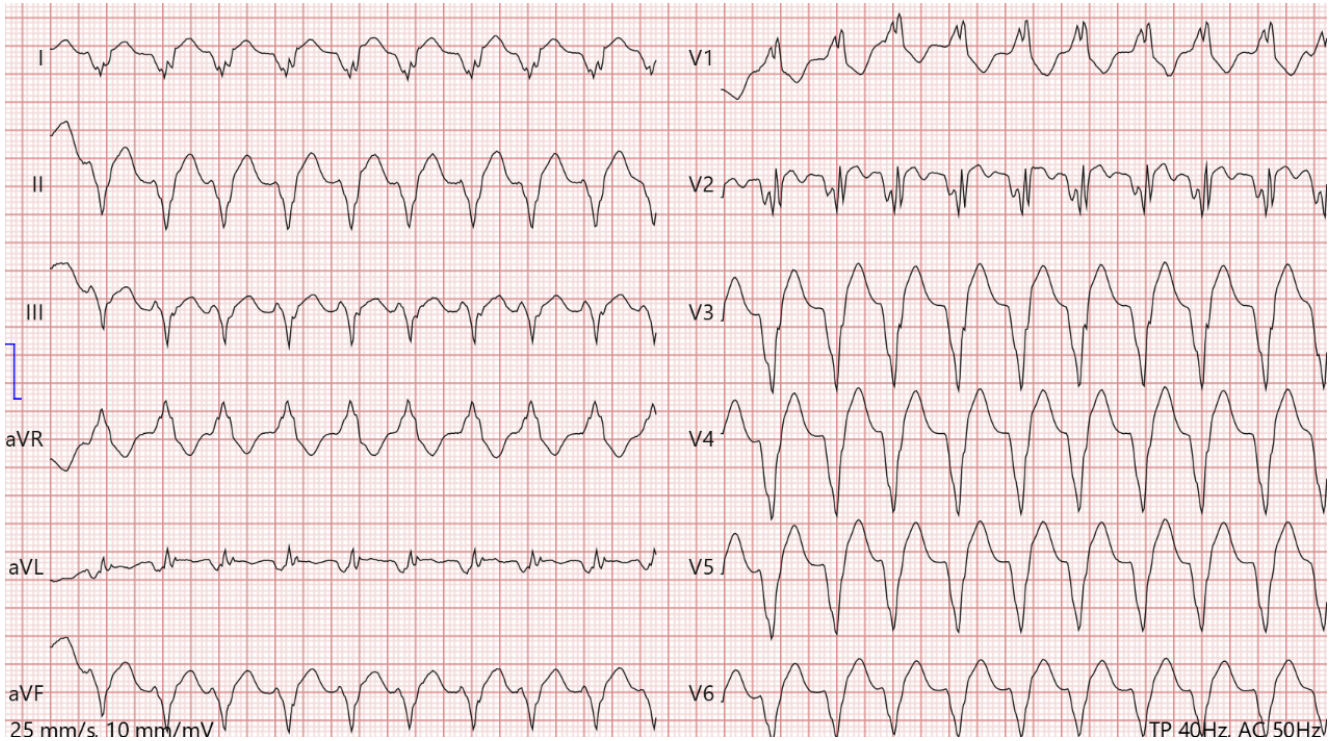

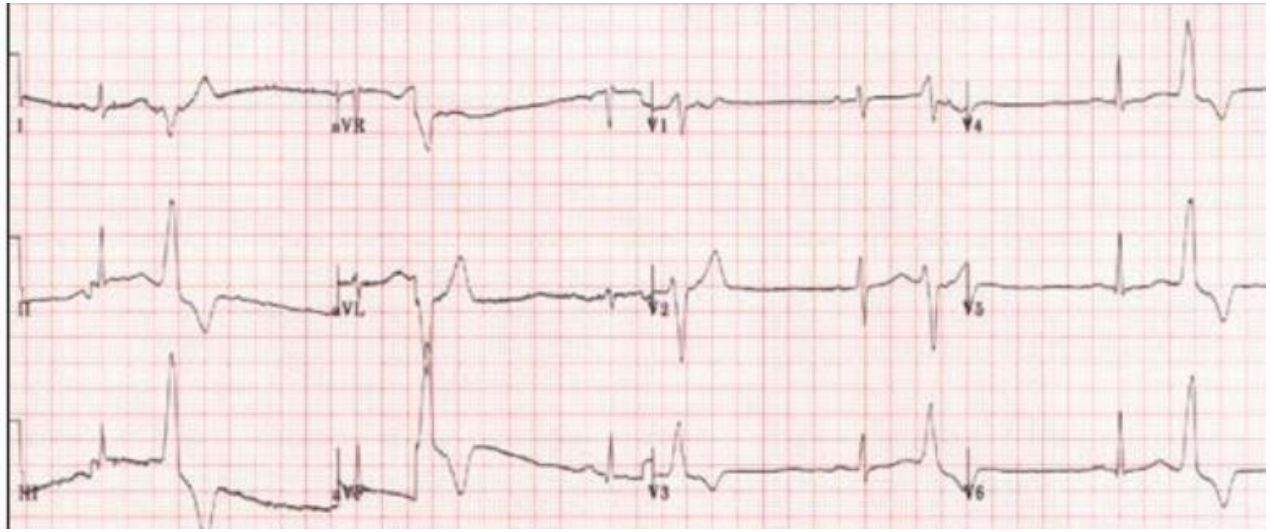

23yr old male Patient

- 12/22 Hospitalisation in Kyjov/Czech Republic
  - girl friend found him lying in bed performing grunting sounds and short episodes of unconsciousness; no alcohol or drug abuse
- Lab, tox screen negativ, CT scan of the brain, echocardiography normal
- ECG SR 70 bpm, PQ, QRS,QT normal, 1 PVC, few NSVTs (max 2 sec during monitoring
- Exercise test, neurological examination normal
- No Family history for SCD; MI,Stroke

Discharged further investigations should be done in Switzerland

However patient did not go to a physician

Maybe NSVT looked like this

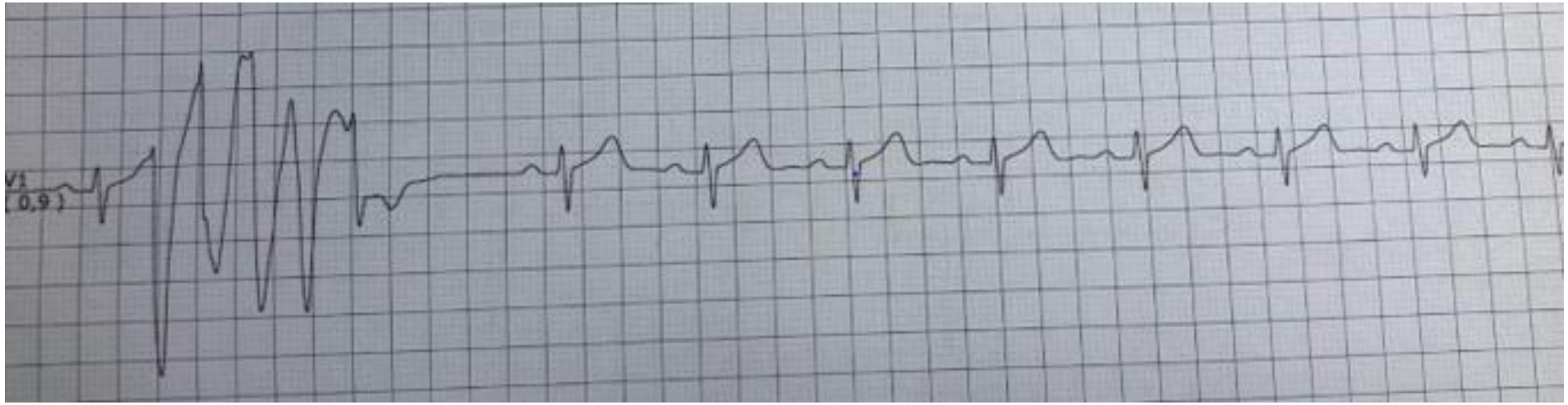

Monomorphic VT
Scare related reentry
Idiopatic VTs

Polymorphic VT
Ischemia
Electrolyte dysbalances
«Genetic»: SCD Long QT, Brugada, CPVT

Back in Switzerland

- Everything was ok
- In April 23 girl friend woke up again at 4:50 due to grunting sounds and seizures like behaviour of her friend
- Hospitalisation in Linth hospital, patient was orientated and awake with SR and normal BP

- Some minutes later….same episode again in hospital

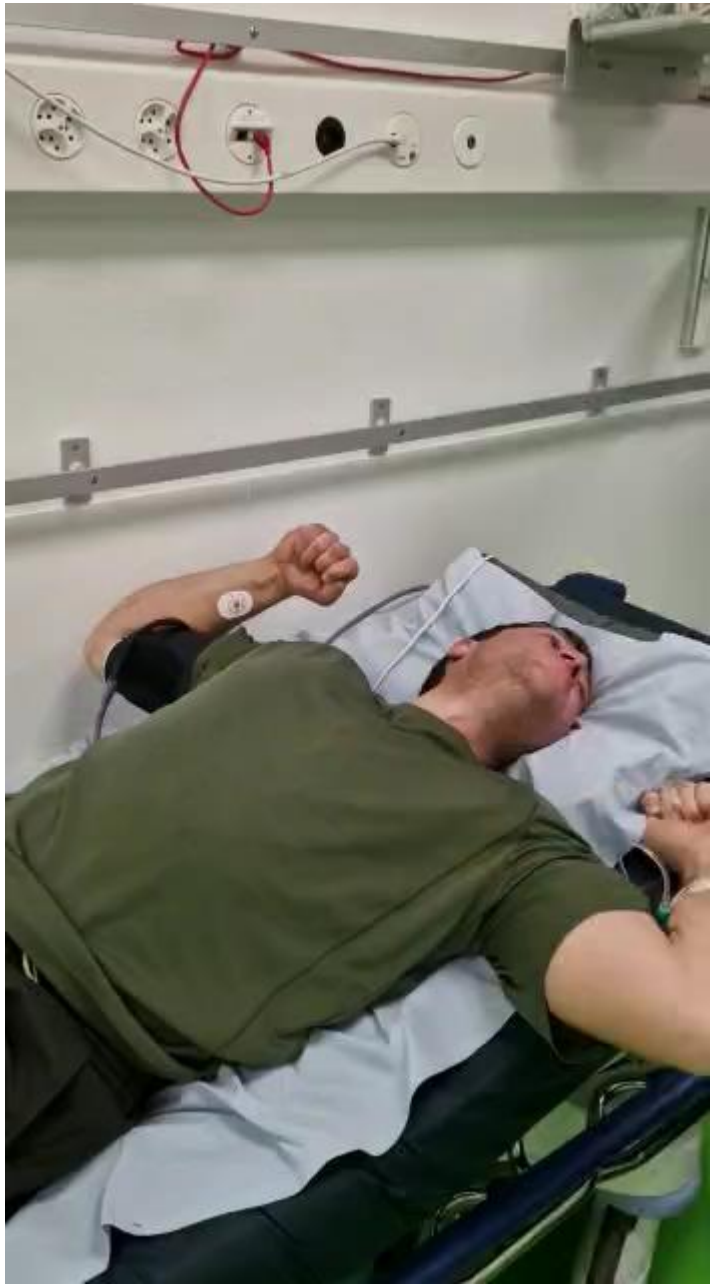

Courtesy from patient

Outomatic defibrillator shocked patient

ECG in software storage

DD VF, VT ? Referred to our hospital

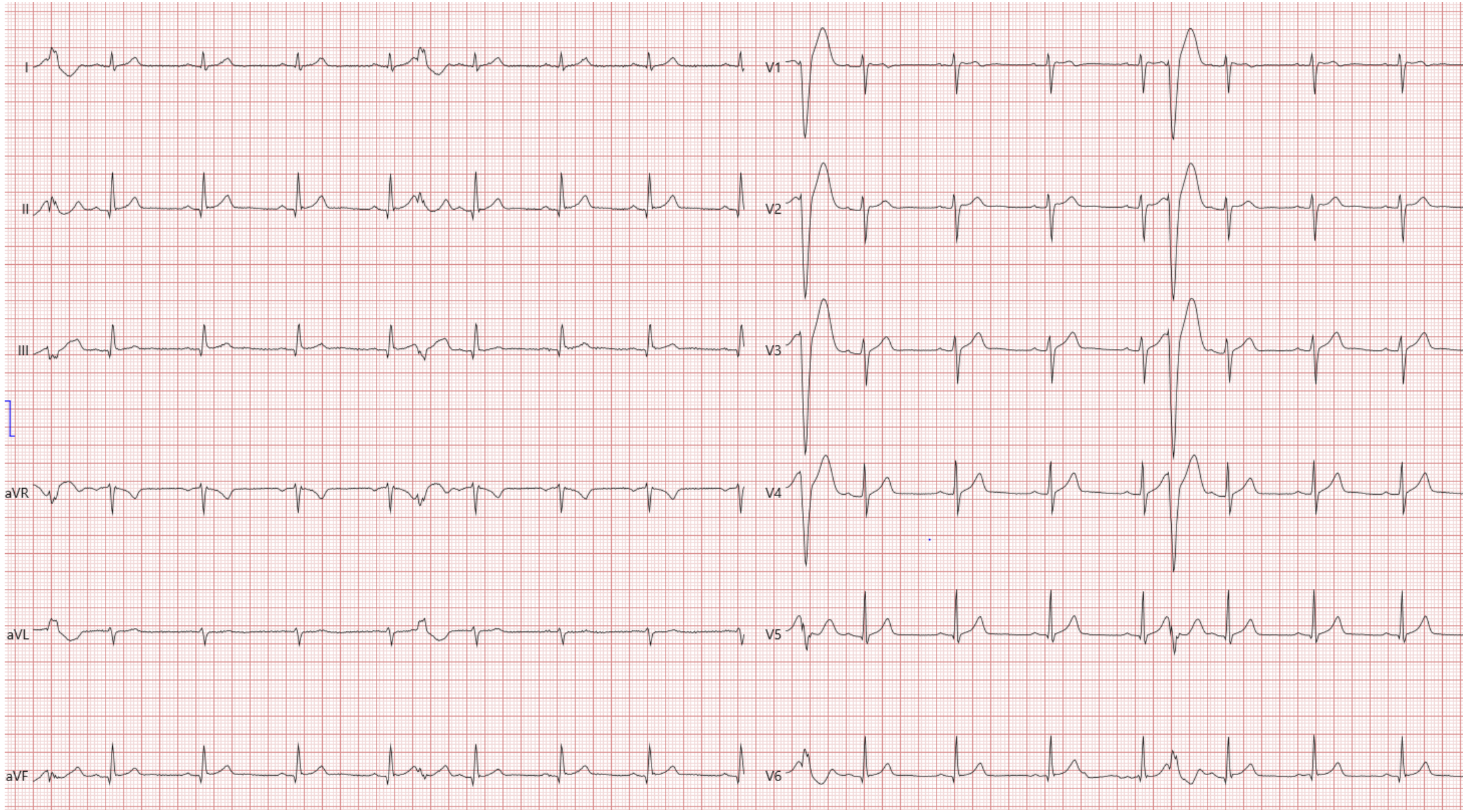
I
II
III
aVR
aVL
aVF
V1
V2
V3
V4
V5
V6

called Dr Nüssli in Linth hospital: can you mail me the stored ECG strip from the defibrillator?

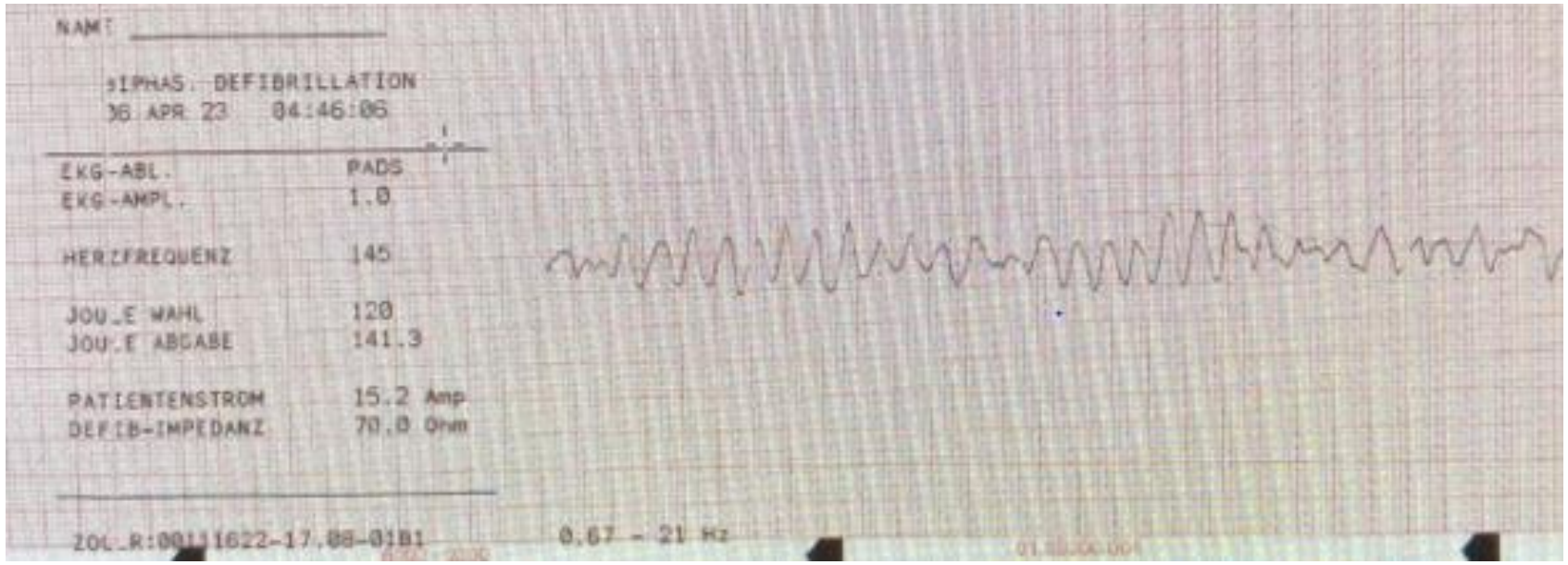

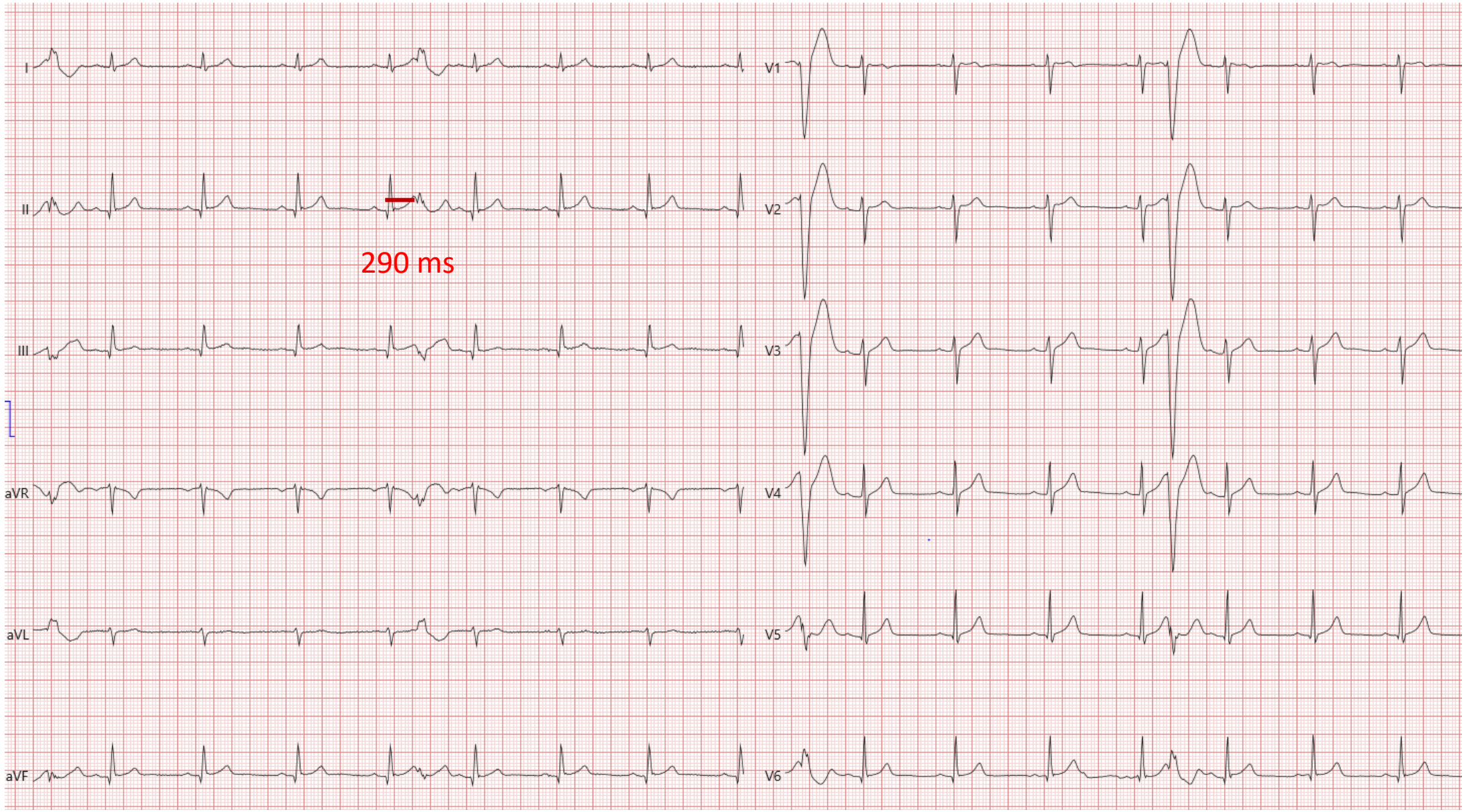
I
II
III
aVR
aVL
aVF
V1
V2
V3
V4
V5
V6
290 ms

Idiopatic Ventricular Fibrillation

- 1957 Long QT syndrom
- 1978 CPVT
- 1992 Brugada syndrome
- 2000 short QT syndrome
- 2013 early repolarization syndrome
- Short coupled torsades de pointes
- DPP6 (2009) ,CALM1 (2014)



Flow chart in our patient

- Unexplained Cardiac arrest (normal ECG, normal Echo normal coronaries)

Minimal assessment	Electrical	Cardiomyopathy	
ECG	LQTS	ACM	Phenotype specific genetic testing&family screening
Coronary imaging	Brugada	HCM	
Echo and CMR	CPVT	DCM	
Exercise testing	SQTS	Myocarditis	
Ajmalin/Flecainid test		Sarcoidosis	

Idiopatic VF (short coupled VF, early Repolarisation)

Greg Mellor EHRA Barcelona 2023

Current management approaches and outcomes for patients with IVF

Recurrent ICD shocks

Acute treatment
Isoprotenerol
Verpamil
Quinidine
Class IIa

Rapid ECG assessment
Ongoing frequent SC-PVCs?

No

Non/infrequent
Anticipate poor result
No access to EP lab

Chronic treament:
Quinidine
(Class IIa)

Yes

Unifocal?
accessible focus?
Ability to ablate acutely?

Catheter ablation of PVC triggers
(Class IIa)

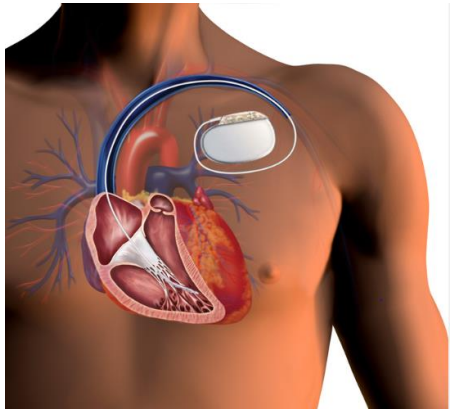

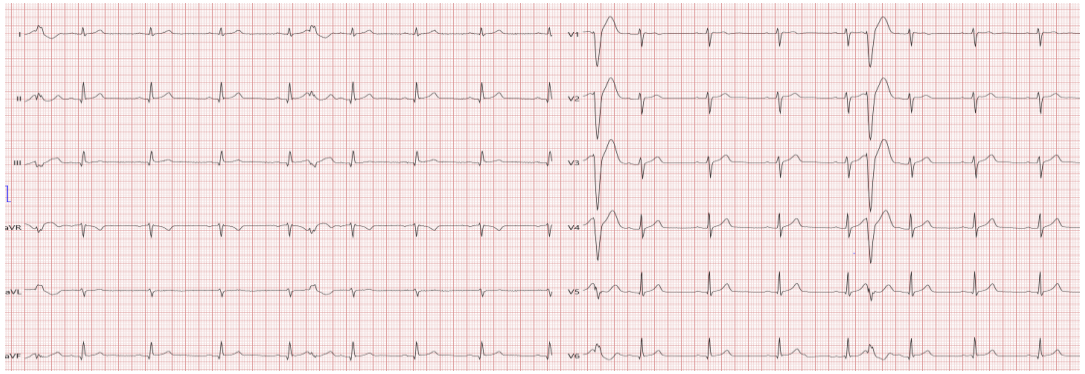

Modified Greg Mellor EHRA Barcelona 23

Discharge

- CT scan coronary arteries normal
- Ajmalin Test normal
- EEG normal
- Concor 2,5 mg, only 3 PVCs/24h, no NSVTs
- ICD implantation
  - «Wathful waiting»

45 yrs old female pts

- Breast cancer 2012
  - Amputation left breast; all FU investigations normal
- Tumor splen sent for biopsy (splenectomie)
  - Sent to our hospital due to ECG

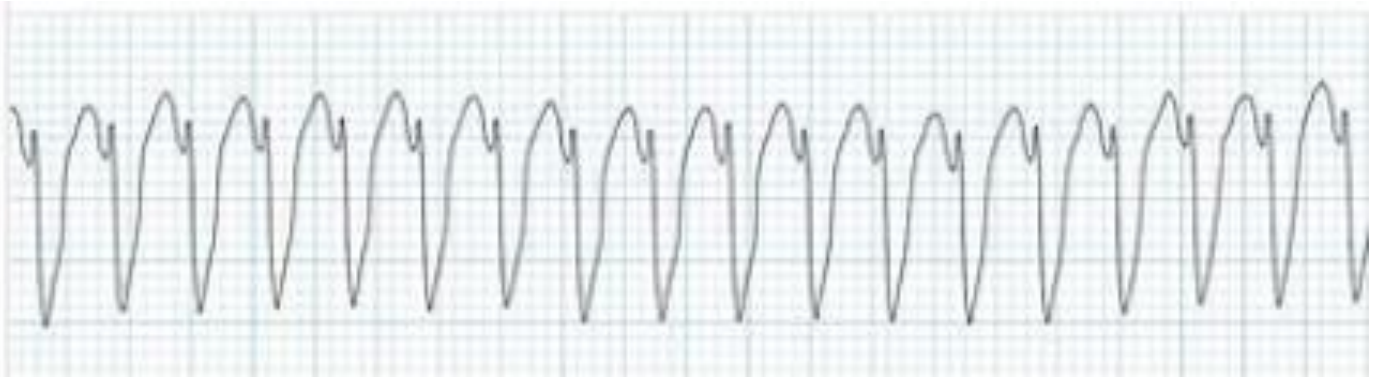

<30 sec

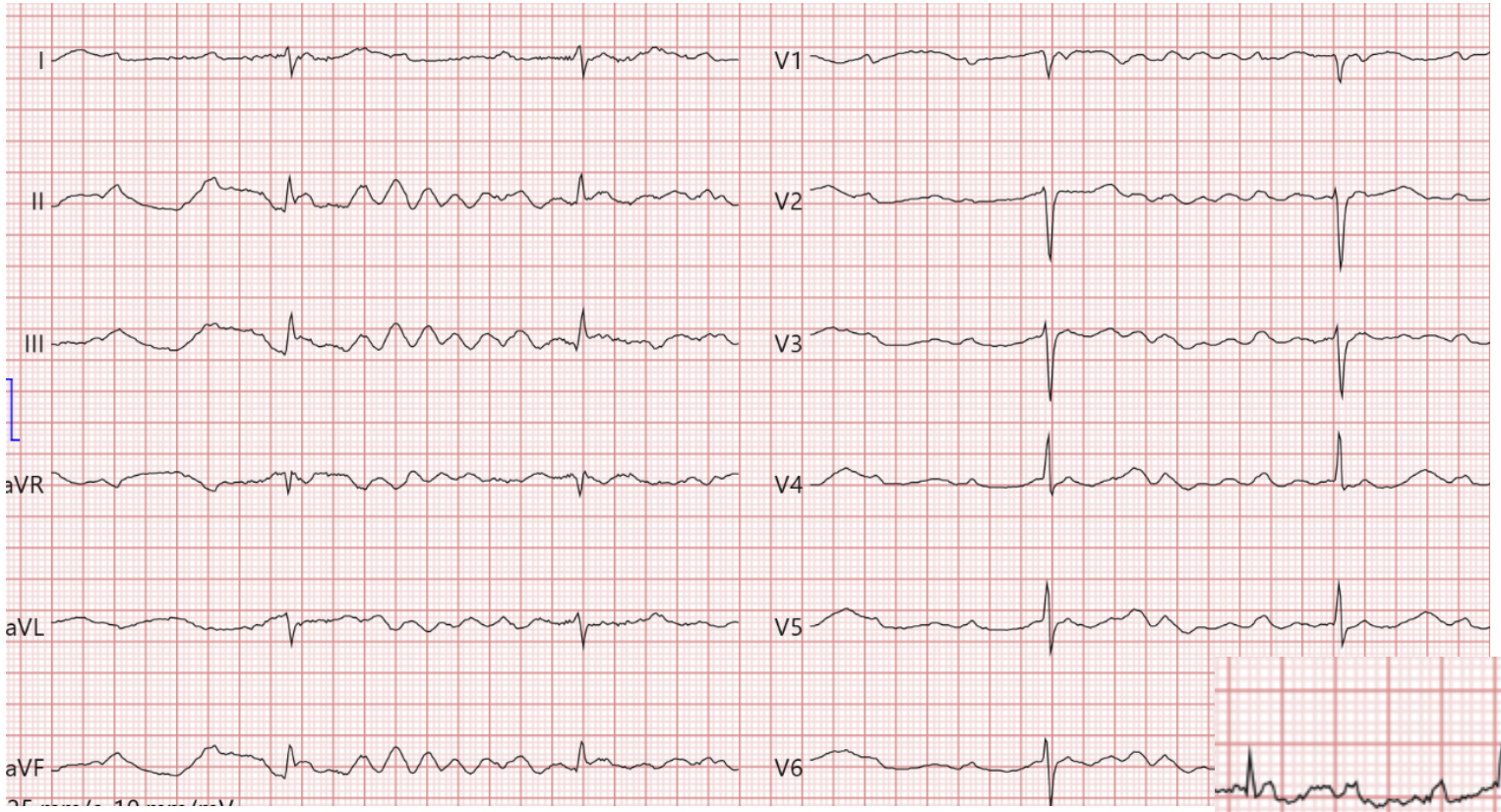

MRI

BEURTEILUNG

V. a. infiltrative Kardiomyopathie

- Normale linksventrikuläre Pumpfunktion (LVEF 58 %)
- Umschriebene intramurale Raumforderung inferior mittkavitär sowie an der Grenze anterior zu anteroseptal basal mit Late-Enhancement im Sinne einer infiltrativen Kardiomyopathie, DD Sarkoidose, Metastasen, nicht auszuschliessen

PET CT

BEURTEILUNG

Glucosestoffwechselaktive Formation mit FDG-Uptake in folgenden Lokalisationen:

- im Myokard anteroseptal
- Hypodenses Weichteilgewebe septal und mediastinal mit Ausbreitung entlang der Gefässe
- in multiplen Lymphknoten hilär bds., mediastinal bds., an der Mammaria interna links, supraklavikulär bds., axillär bds., retroperitoneal, iliakal bds. und inguinal bds. rechtsbetont.
- in 2 pulmonalen Rundherden unmittelbar den Gefässen proximal im Oberlappen bds. anliegend
- im grossen hypodensen Milzherd

Die Befunde sind vorbestehend im CT Thorax/Abdomen vom 7.8.2019, teilweise leicht progredient.

Die Gesamtkonstellation ist vereinbar mit einem ausgedehnten Sarkoidosebefall mit kardialer Beteiligung, DD ebenfalls gut möglich ist ein Lymphom, DD Metastasen des Mammakarzinoms wenig wahrscheinlich.

Transbronichial biopsy

35411-2:

Lymphknoten Nr. 7 mit Fragmenten aus produktiven Granulomen sowie lymphatische Strukturen, Befunde vereinbar mit Sarkoidose. Keine Malignität.

Therapie VES/VTs

- Idiopatische
  - Asymptomatisch, normale LVEF: watchful waiting
  - Symptomatisch, LVEF eingeschränkt: Ablation vs BB/Verapamil
- Strukturelle KMP
  - Behandlung der Grunderkrankung eg KHK, Sarkoidose
  - ICD/CRT-D? (LVEF < 35%, LSB) falls CRT- 98% biv pacing?
  - Ablation bei ischämischer KMP einfach
  - Ablation bei NICMP schwierig
  - BB, Amiodaron (Flecainid, Amiodaron, Quinidine)

Question: 62 yrs old man with syncope AV Block III and NSVT (4 PVCs, monomorphic 140 bpm) discuss further investigations:

- A) implant a DDD PM
- B) implant a VDD Micra
- C) perform coronary CT scan before PM implantation
- D) perform MRI
- E) implant a DR ICD
- F) implant a VR ICD
- G) perform thoracic CT scan
- H) exclude Lyme disease

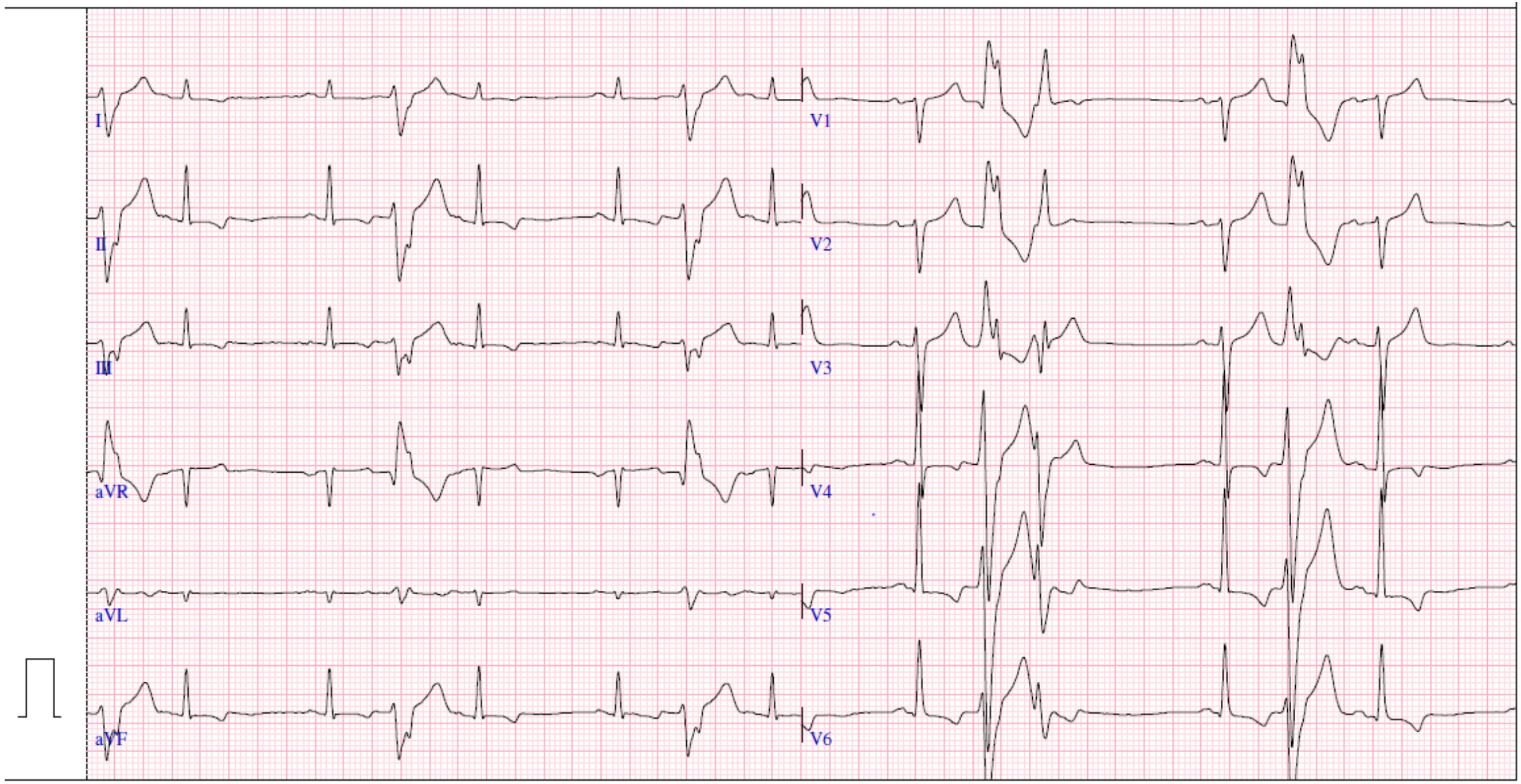
I
V1
II
V2
III
V3
aVR
V4
aVL
V5
aVF
V6

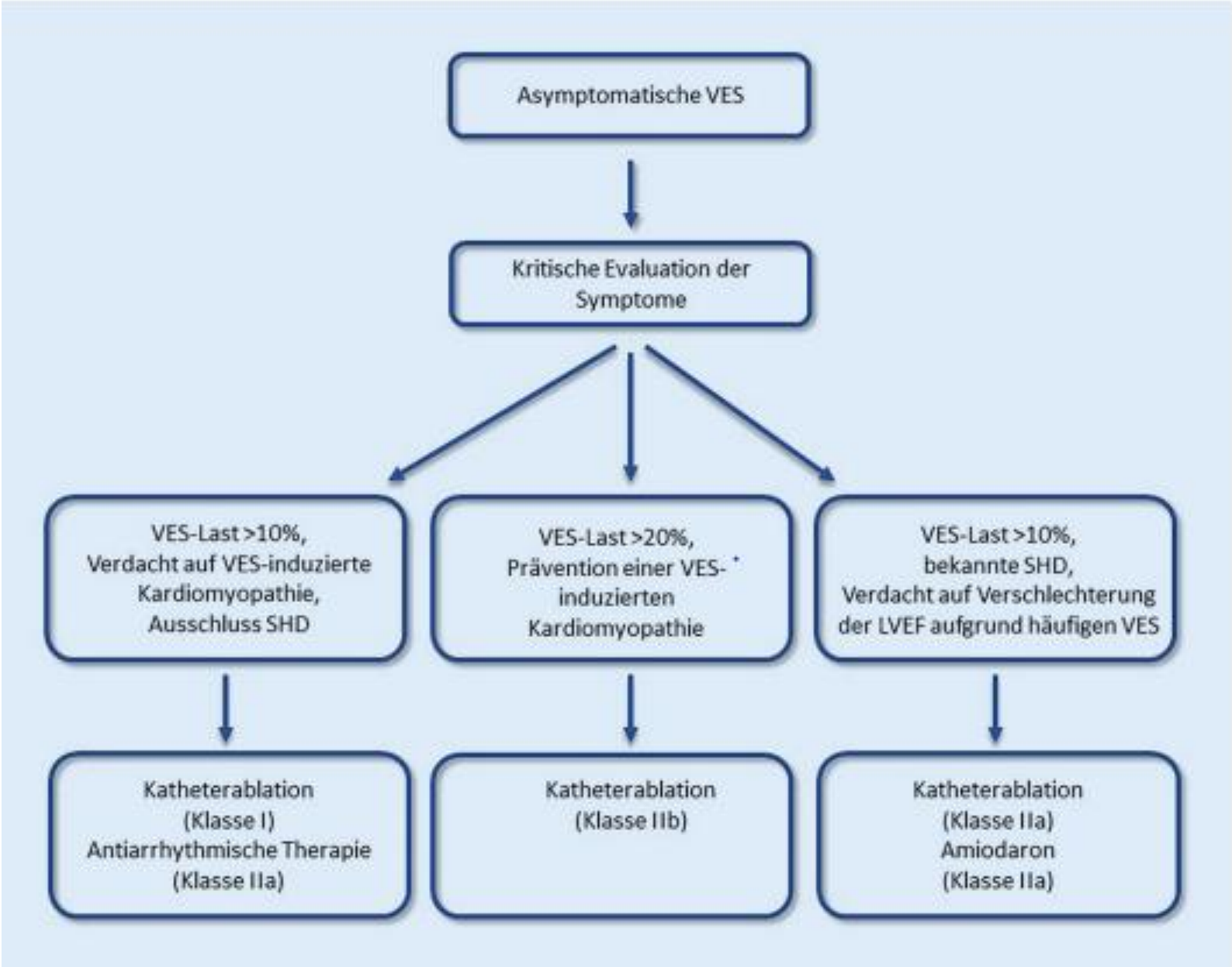
Asymptomatische VES
Kritische Evaluation der Symptome
VES-Last >10%, Verdacht auf VES-induzierte Kardiomyopathie, Ausschluss SHD
VES-Last >20%, Prävention einer VES-induzierten Kardiomyopathie
VES-Last >10%, bekannte SHD, Verdacht auf Verschlechterung der LVEF aufgrund häufigen VES
Katheterablation (Klasse I) Antiarrhythmische Therapie (Klasse IIa)
Katheterablation (Klasse IIb)
Katheterablation (Klasse IIa) Amiodaron (Klasse IIa)

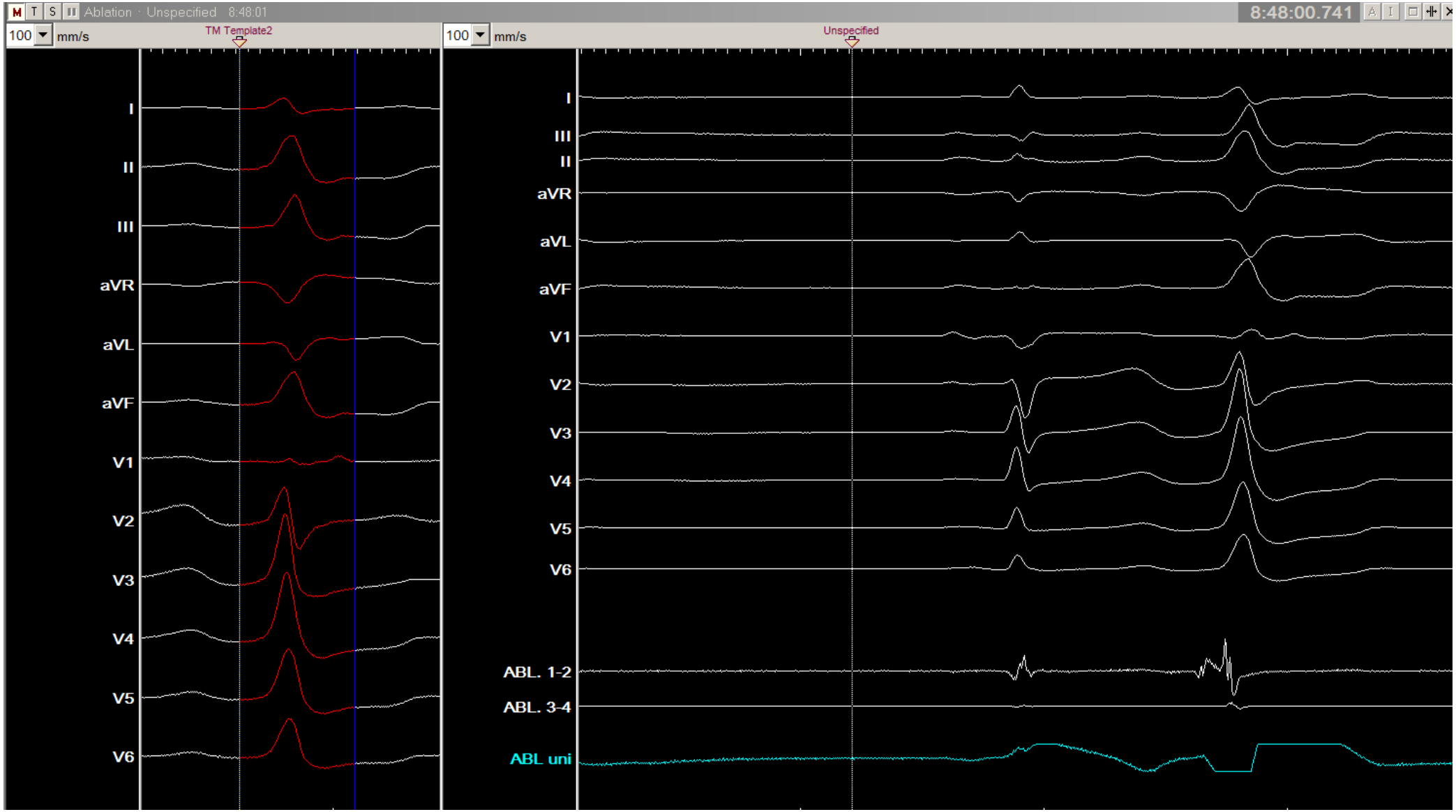
Ablation · Unspecified 8:48:01
8:48:00.741
100 mm/s
TM Template2
100 mm/s
Unspecified
I
II
III
aVR
aVL
aVF
V1
V2
V3
V4
V5
V6
I
III
II
aVR
aVL
aVF
V1
V2
V3
V4
V5
V6
ABL. 1-2
ABL. 3-4
ABL uni

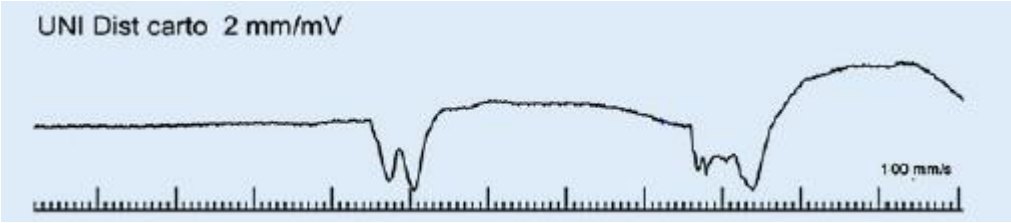
UNI Dist carto 2 mm/mV
100 mm/s

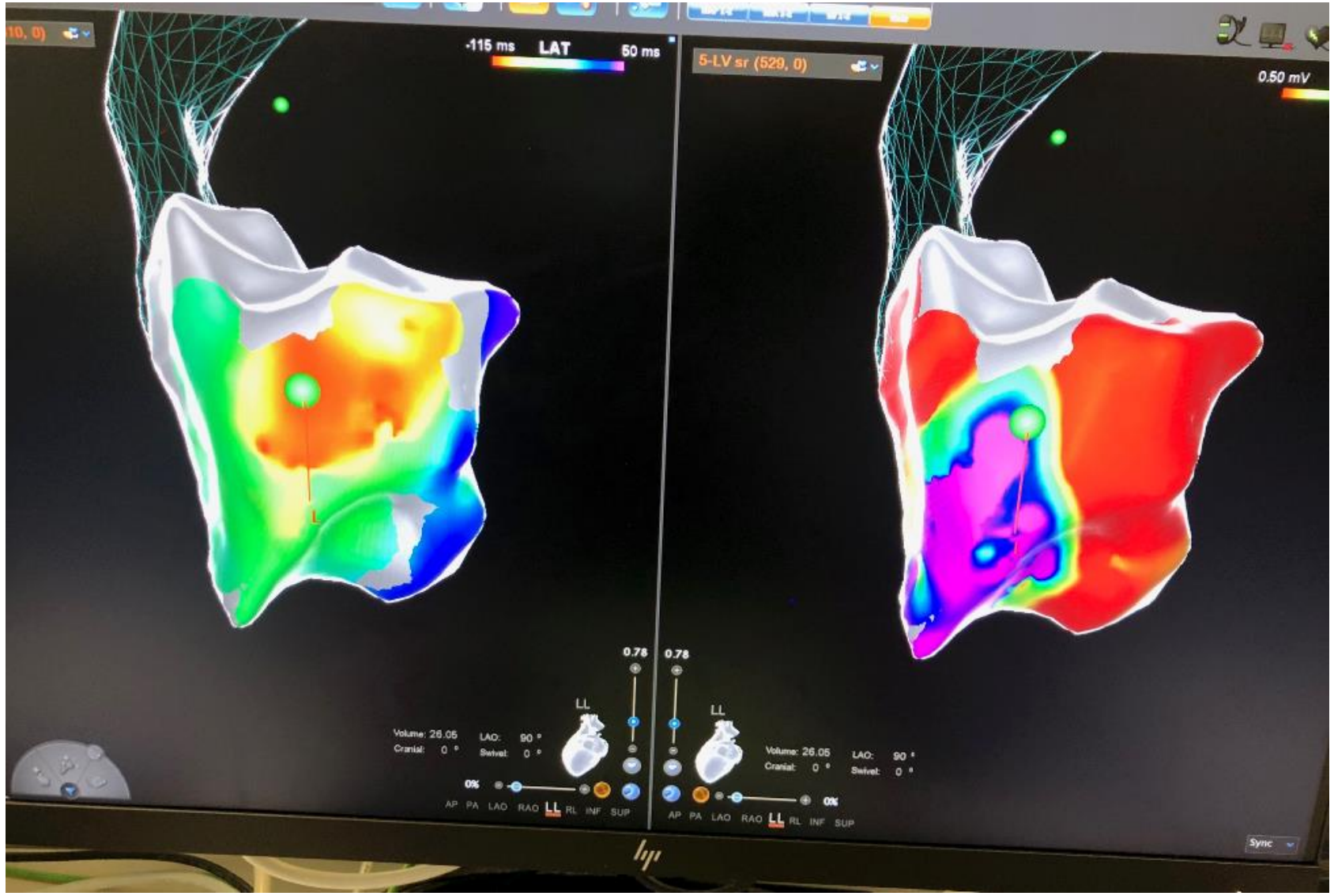
-115 ms
LAT
50 ms
5-LV sr (529, 0)
0.50 mV
0.78
LL
Volume: 26.05
Cranial: 0 °
LAO: 90 °
Swivel: 0 °
0%
AP PA LAO RAO LL RL INF SUP
Sync

	Conduction Abnormality	*Repolarization Abnormality*	*Excitation Abnormality*
Primary VF substrate	**Structural abnormality - Heterogeneity of depolarization**	**Electrical abnormality - heterogeneity of repolarization**	**Rapid or multifocal ectopic activity**
	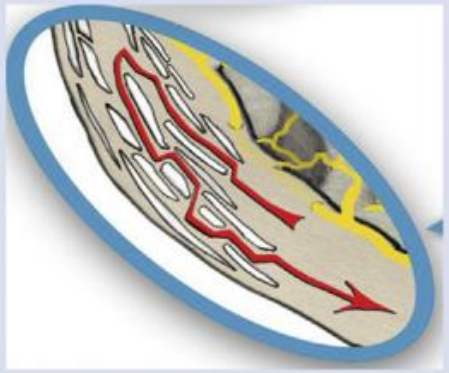	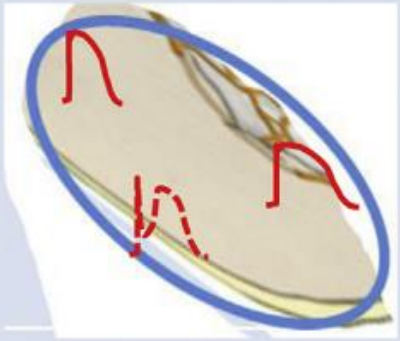	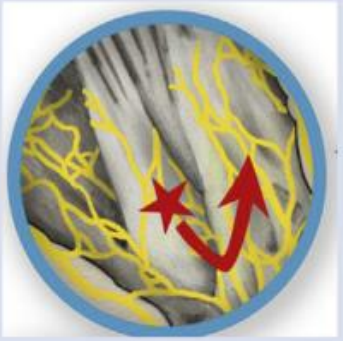
Diagnostic	*Localized prolonged depolarization*	*Repolarization parameters*	*Consistent Ectopy at arrhythmia initiation and no myocardial abnormality*
Type	**Brugada syndrome** **Inferolateral J wave** **IVF with localized structural abnormality**	**Long QT** **Early repolarization** **Short QT**	**IVF from Purkinje or myocardial foci** **Catecholaminergic Polymorphic VT** **Accidental : Commotio cordis, electrocution, drugs ..**
Therapy	***Ablation***	***Drugs***	***Drugs or Ablation***

Haissaguerre et al Card Electrophysiol Clin 2019