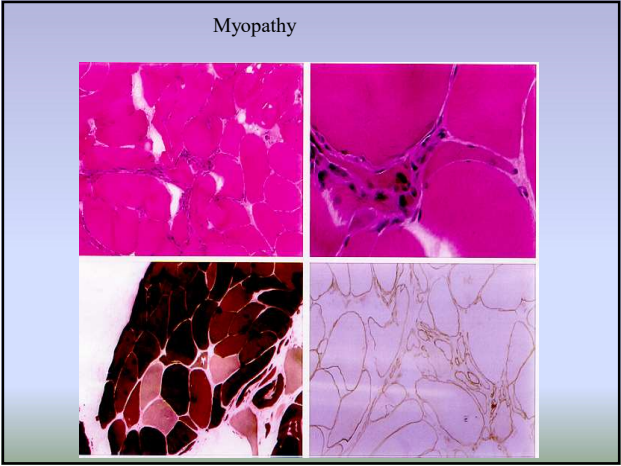
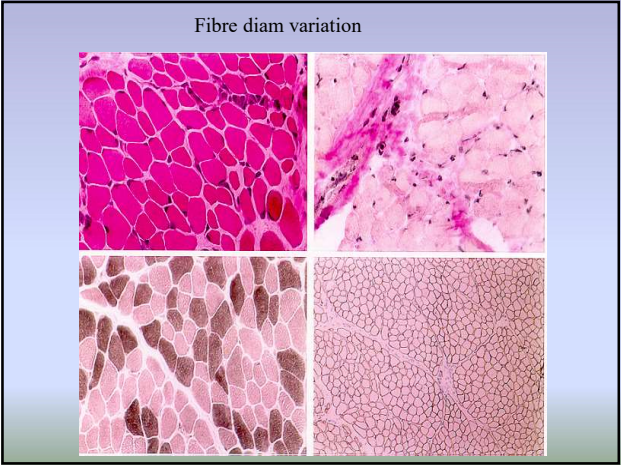
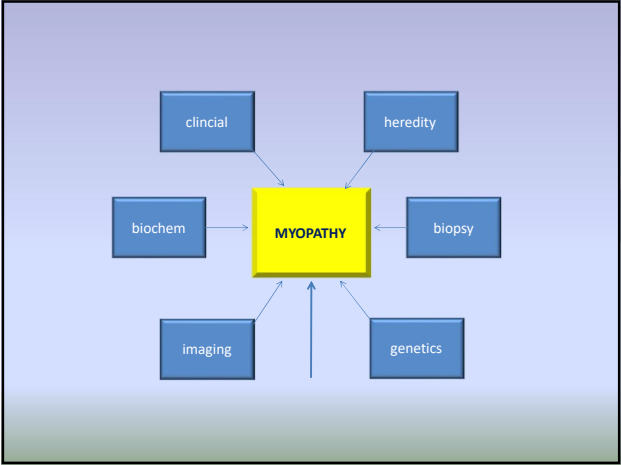


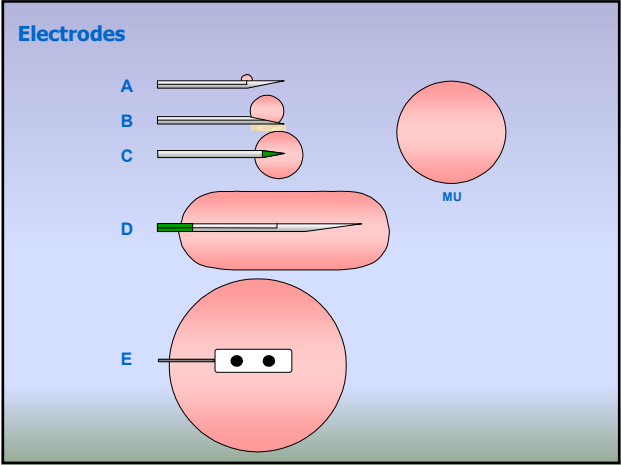
EMG in MYOPATHY

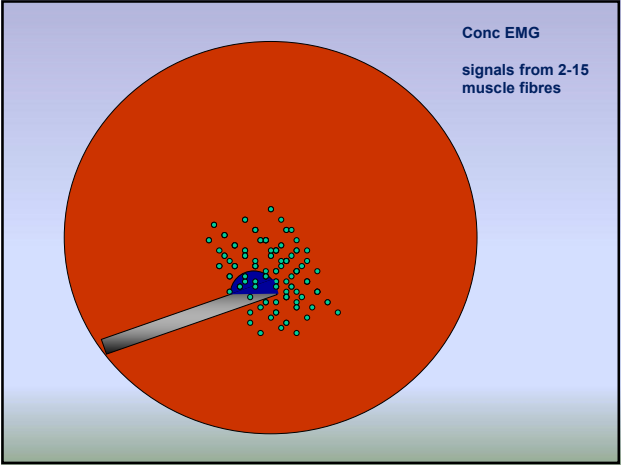
Which information do we get from EMG today?

Erik Stålberg
Uppsala, Sweden



- 1. Background to typical "myopathic" EMG findings
- 2. Situations where EMG gives "unique" information





CNEMG

- **At rest** denervation and spec spontaneous activity (myotonia, CRD, neuromyotonia)
- MUP number of fibres in recorded area
fibre diameters
n-m transmission
- IP recruitment pattern
total number of MUs at full effort

Spontaneous activity from the muscle

FINDING

- fibrillation potentials, psw
- myotonic discharges
- CRD
- myokymic discharges
- myogenic extra discharges

QUANTIFY AS

- #/ 10 recording sites
- or +, ++, +++, ++++
- few
- moderate
- abundant
- or
- spontaneous or
- after provocation

Stålberg

Spontaneous activity from the nerve

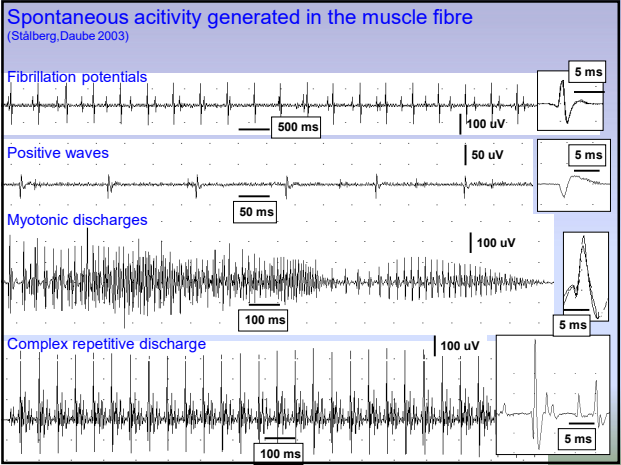
FINDING

- neuromyotonic discharges
- myokymic discharges
- muscle cramps
- fasciculations
- neurogenic extra discharges

QUANTIFY AS

- #/ 10 recording sites
- or +, ++, +++, ++++
- Few (per time unit)
- moderate
- abundant
- or
- spontaneous or
- after provocation

Stålberg



Spontaneous activity in myopathy

Fib, PSW ?	Yes	→	Muscular dystrophies
Myotonic Disch. ?	No		Myositis, IBM
CRD ?	No		Debrancher Glycogenosis
			Acid Maltase Deficiency
			Hyperkalemic per paralysis
			Myotonic conditions
			LGMD 1A
			Nemaline myopathy
			Myotubular myopathy
			Mitochondrial myopathy
			Carnitine Deficiency
			Hypothyroid myopathy
			Rhabdomyolysis
			Toxic
			– Chloroquine
			– Alcoholic
			– Statins
			– Colchicine

Courtesy R. Liguori, modified

Spontaneous activity in myopathy

Fib, PSW ?	Yes	→
Myotonic Disch. ?	Yes	→
CRD ?	No	

Muscular dystrophies
Myositis, IBM
Debrancher Glycogenosis
Acid Maltase Deficiency
Hyperkalemic per paralysis
Myotonic conditions
LGMD 1A
Nemaline myopathy
Myotubular myopathy
Mitochondrial myopathy
Carnitine Deficiency
Hypothyroid myopathy
Rhabdomyolysis
Toxic
- Chloroquine
- Alcoholic
- Statins
- Colchicine

Spontaneous activity in myopathy

Fib, PSW ?	Yes	→
Myotonic Disch. ?	Yes	→
CRD ?	Yes	→

Muscular dystrophies
Myositis, IBM
Debrancher Glycogenosis
Acid Maltase Deficiency
Hyperkalemic per paralysis
Myotonic conditions
LGMD 1A
Nemaline myopathy
Myotubular myopathy
Mitochondrial myopathy
Carnitine Deficiency
Hypothyroid myopathy
Rhabdomyolysis
Toxic
- Chloroquine
- Alcoholic
- Statins
- Colchicine

Spontaneous activity in myopathy

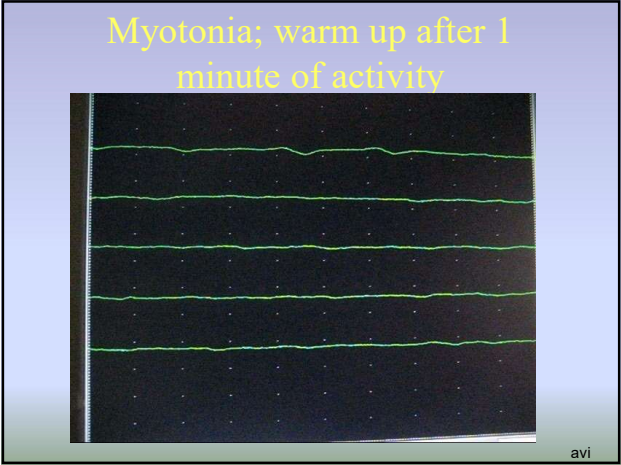
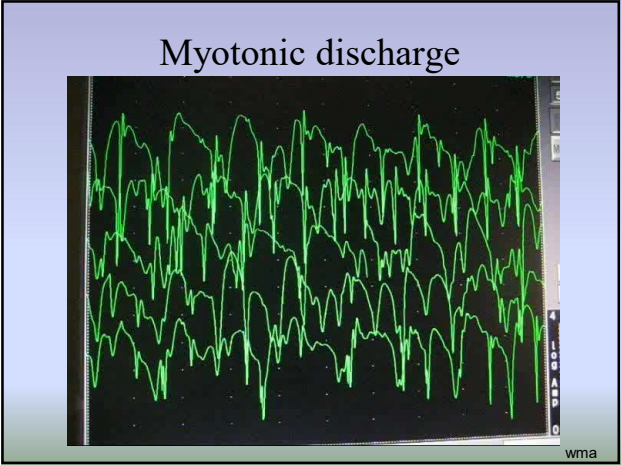
Fib, PSW ?	Yes	→
Myotonic Disch. ?	No	
CRD ?	Yes	→

Muscular dystrophies
Myositis, IBM
Debrancher Glycogenosis
Acid Maltase Deficiency
Hyperkalemic per paralysis
Myotonic conditions
LGMD 1A
Nemaline myopathy
Myotubular myopathy
Mitochondrial myopathy
Carnitine Deficiency
Hypothyroid myopathy
Rhabdomyolysis
Toxic
- Chloroquine
- Alcoholic
- Statins
- Colchicine

Spontaneous activity in myopathy

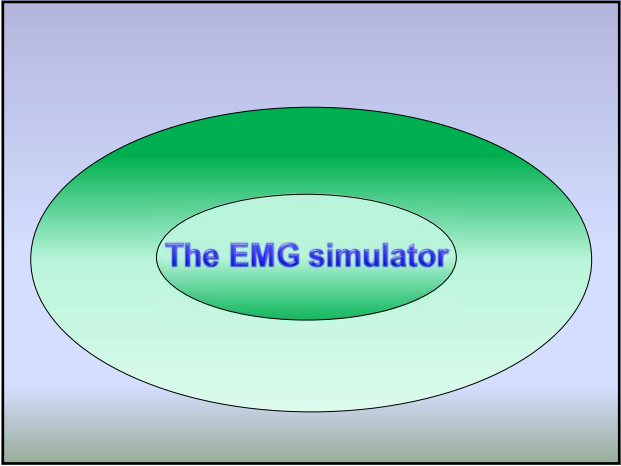
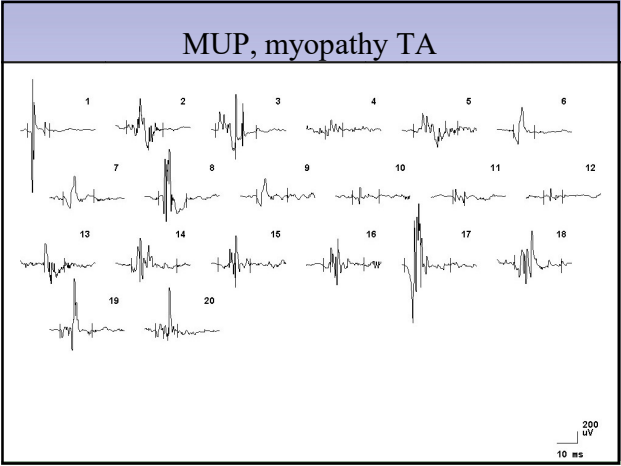
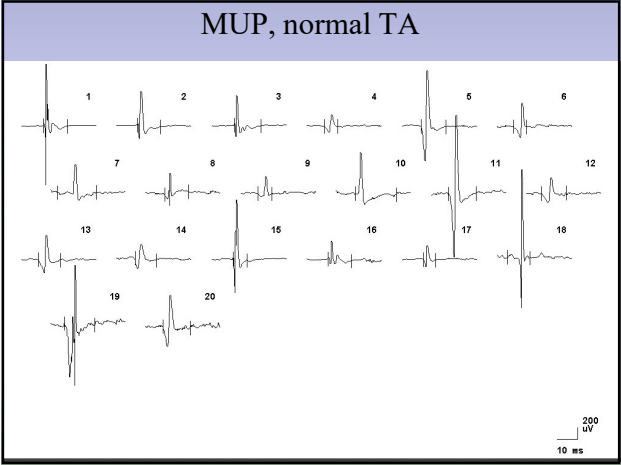
Fib, PSW ?	No	
Myotonic Disch. ?	Yes	→
CRD ?	No	

Muscular dystrophies
Myositis, IBM
Debrancher Glycogenosis
Acid Maltase Deficiency
Hyperkalemic per paralysis
Myotonic conditions
LGMD 1A
Nemaline myopathy
Myotubular myopathy
Mitochondrial myopathy
Carnitine Deficiency
Hypothyroid myopathy
Rhabdomyolysis
Toxic
- Chloroquine
- Alcoholic
- Statins
- Colchicine



CNEMG

- **At rest** denervation and spec spontaneous activity (myotonia, CRD, neuromyotonia)
- **MUP**
 - number of fibres in recorded area
 - fibres diameters
 - n-m transmission
- **IP**
 - recruitment pattern
 - total number of MUs at full effort



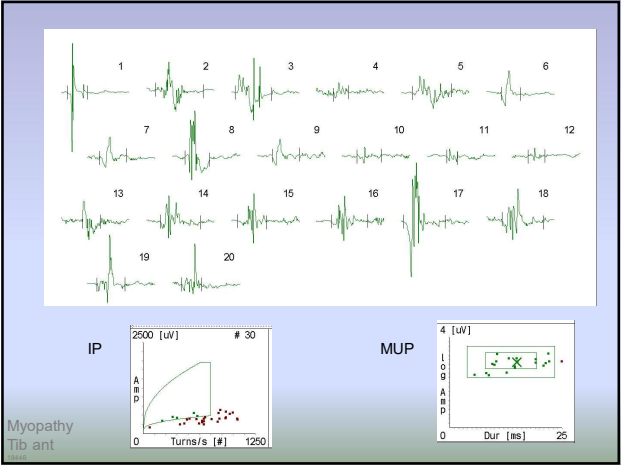
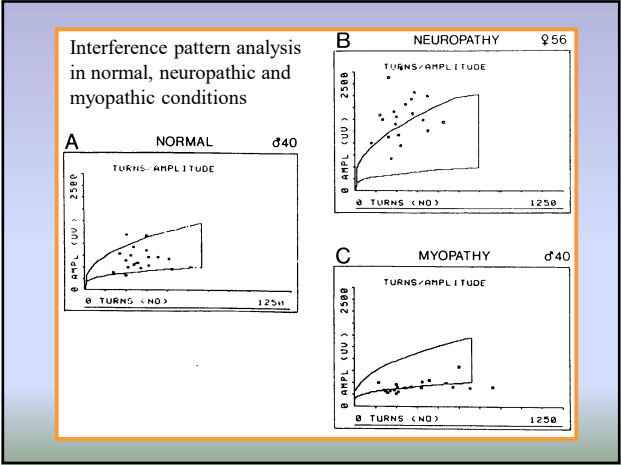
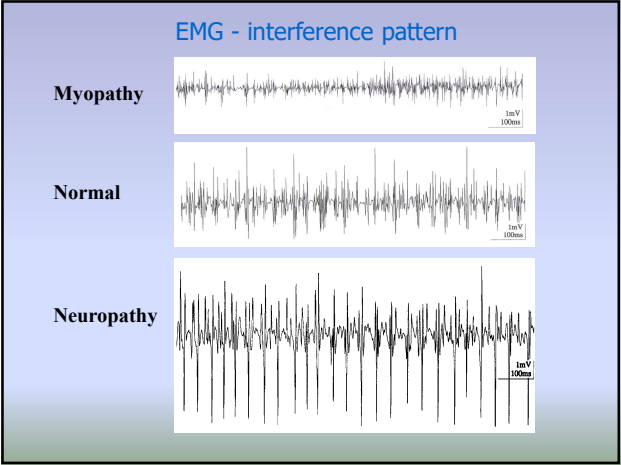
Emery-Dreifuss muscular dystrophy, X-linked type 1 (EDMD; emerinopathy)

Mild to moderate dystrophic changes: Fiber size variation, a few necrotic fibers, central nuclei, increase of fibrous connective tissue and fat between myofibers.

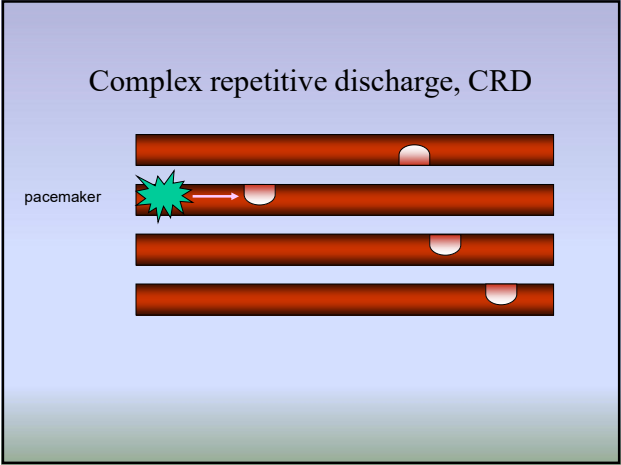
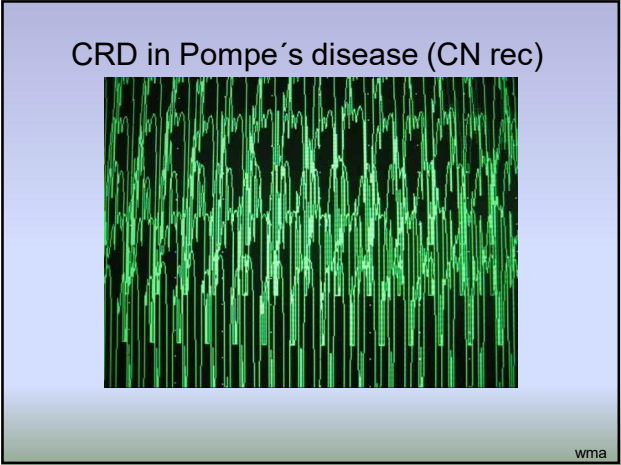
Courtesy Kallimo, 2010

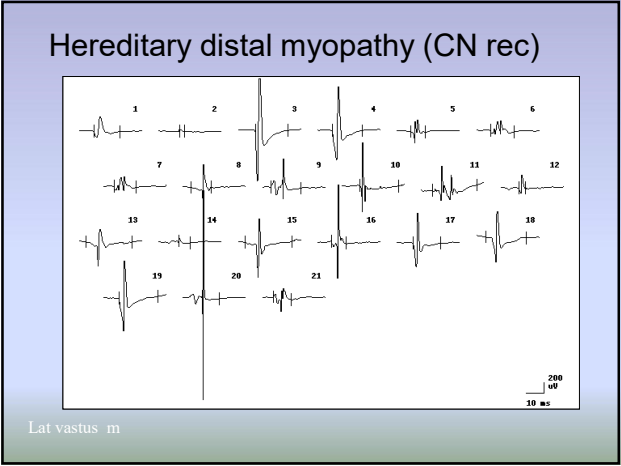
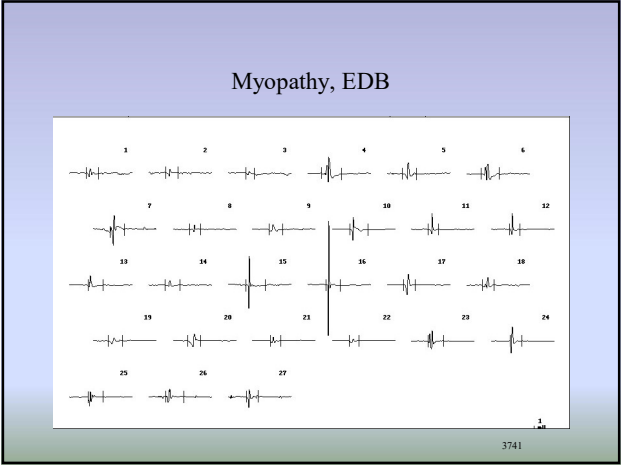
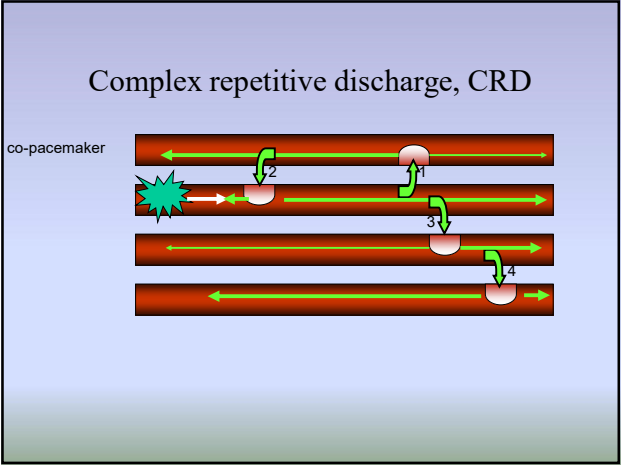
CNEMG

- **At rest** denervation and spec spontaneous activity (myotonia, CRD, neuromyotonia)
- **MUP**
 - number of fibres in recorded area
 - fibres diameters
 - n-m transmission
- **IP**
 - recruitment pattern
 - total number of MUs at full effort

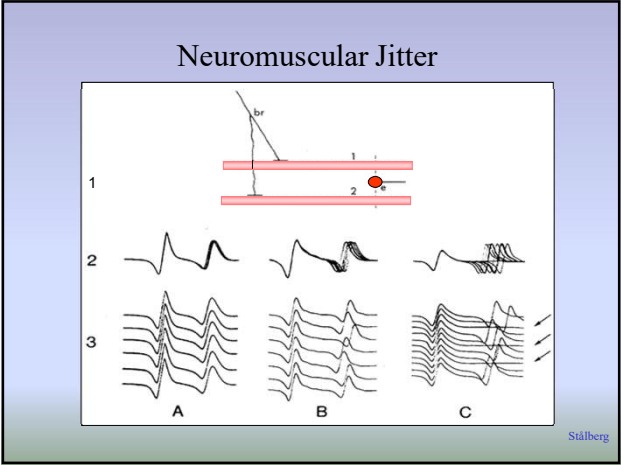
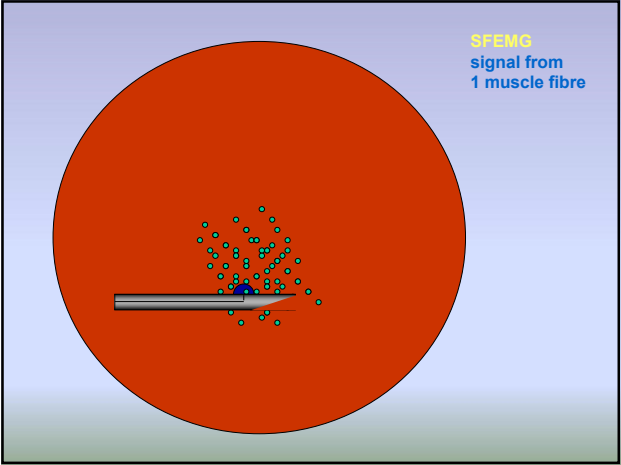


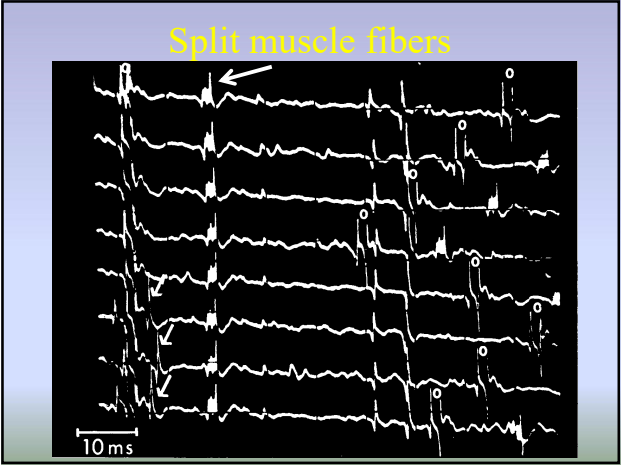
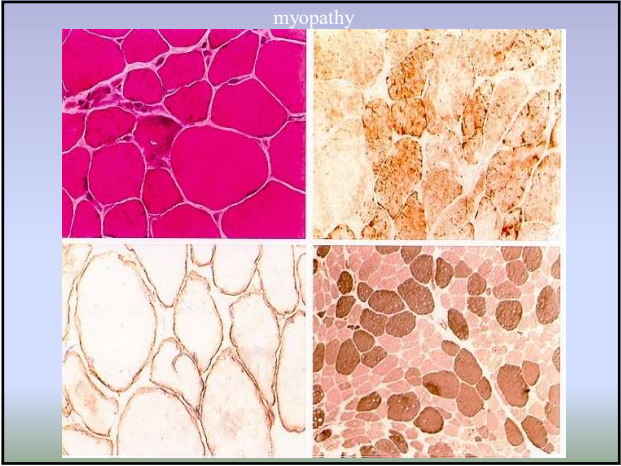
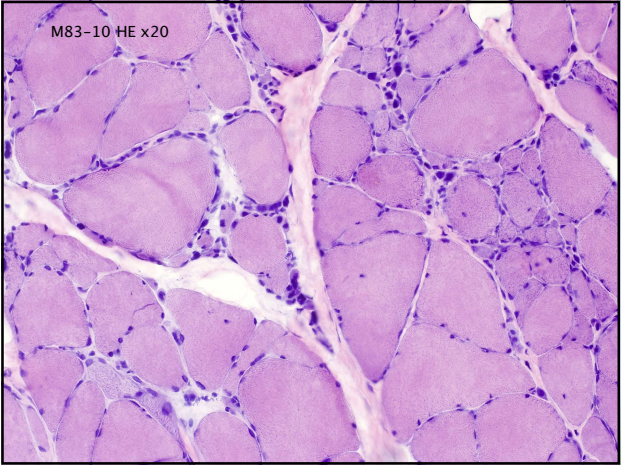
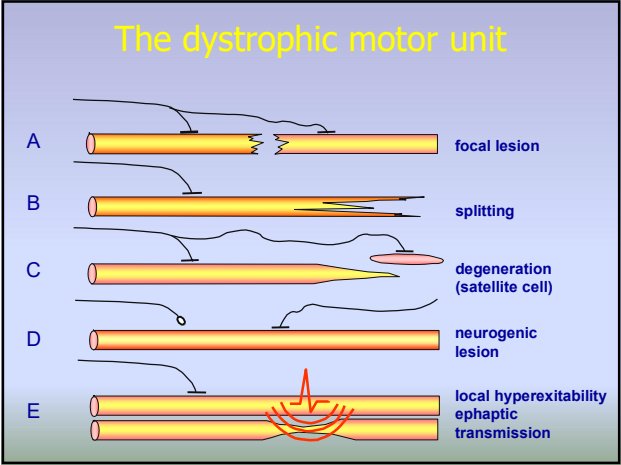
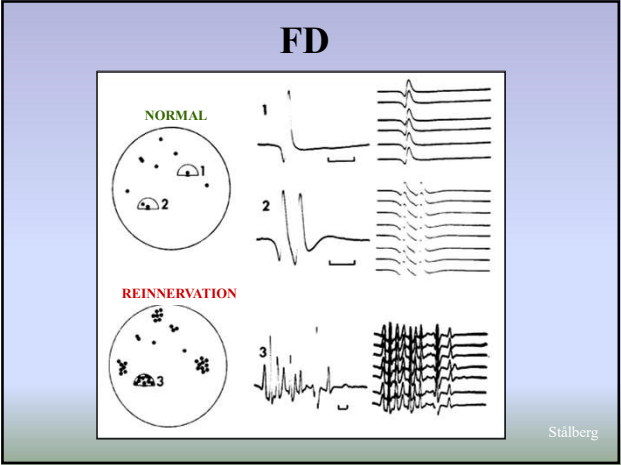
Beyond conventional EMG





Other EMG methods

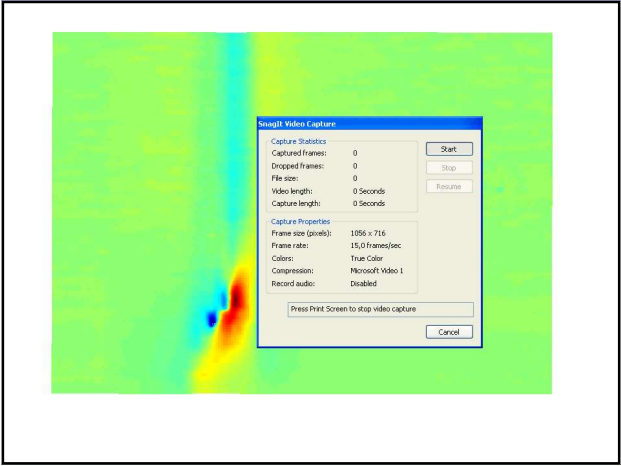
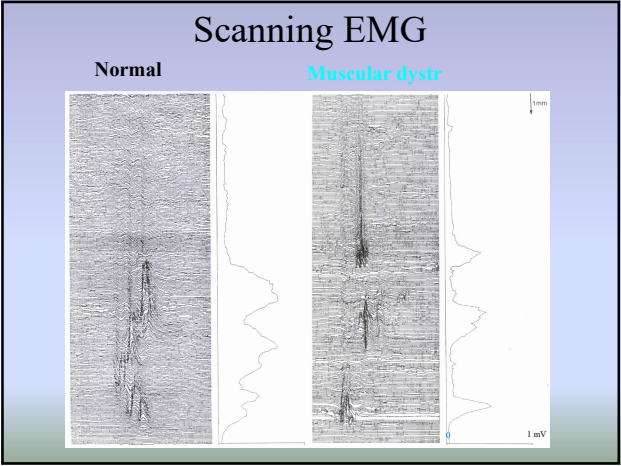

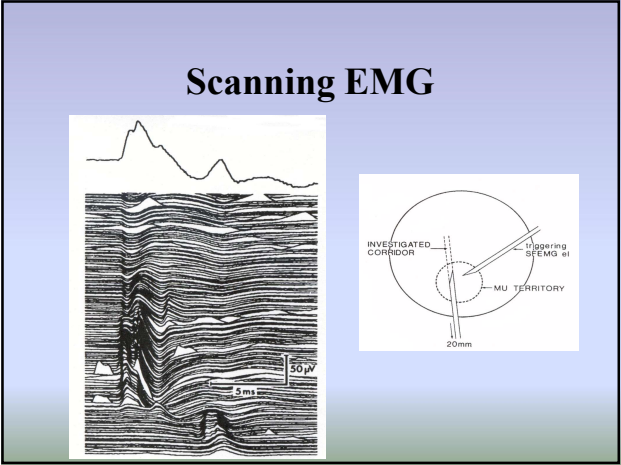




EMG and MU organisation

	Normal			Reinn	Myopathy
• MUP ampl	n	n	n	↑	↓
• FD	n	n	n	↑	↑
• Macro ampl	↓	n	↑	↑↑	n ↓

Stålberg



Sensitivity/specificity of EMG in Myopathies

- **Sensitivity** (abnormal vs normal):
 - depends on type of myopathy:
 - Duchenne, myositis..... 90-99%
 - Metabolic myopathymay be very low
- **Specificity** (classification):
 - EMG usually not specific in separating subgroups

EMG combined with other findings gives a clue

- Myopathy +Neuropathy;
 - think of mitochondrial dysfunction,
 - malignancy
- Normal EMG in clinical myopathy;
 - think of metabolic myopathy
- Performance/EMG discrepancy;
 - Weakness + full EMG pattern myopathy
 - Weakness + normal MUPs central

Indications for EMG

•**Weakness/fatigue**

- central
- motor neurone
- peripheral nerve; pnp, focal
- muscle (nm-j, myopathy, periodic weakness)

•**Numbness**

•**Cramps**

- myotonia, ben. fasc. syn., neurotonia, stiff p. syn

•**Pain**

•**ICU**

- Critical illness...

Indications for EMG and myopathy

•**Weakness/fatigue**

- central
- motor neurone
- peripheral nerve; pnp, focal
- muscle (nm-j, myopathy, periodic weakness)

•**Cramps**

- myotonia, ben. fasc. syn., neurotonia, stiff p. syn

•**Pain**

•**ICU**

- Critical illness...