UNIVERSITÄTS-
KINDERSPITAL
ZÜRICH

«Kinderherzchirurgie:
- Wie alles begann und wo wir heute stehen…»

Weihnachtskolloquium – KSSG 30.11.2022

Kinderherzchirurgie – Kinderspital Zürich

Robert Cesnjevar, Hitendu Dave,
Martin Schweiger, Dominikus Schullerer,
Clemens Haselmann und
Luigi di Pasquale

Das Spital der Eleonorenstiftung

Häufigkeit angeborener Herzfehler

- angeborene Herzfehler sind die häufigsten angeborene Fehlbildungen!
- 8-10 pro Tausend in der BRD (ca. 1%), ca. 6000 Kinder pro Jahr
- etwa die Hälfte davon muss im 1. Lebensjahr operiert werden
- d.h. für die Schweiz ca. 600 Kinder pro Jahr (ca. 300 Operationen)
- nicht-zyanotische Herzfehler („pink babies“)

  VSD, VSD, AV-Kanal, PDA ....
- zyanotische Herzfehler („blue babies“)

  Fallot, TGA ...
- univentrikuläre Herzen

  HLHS, Trikuspidalatresie ...

Maud Abbot - natürlicher Verlauf

- Pathologin
- Systematische Klassifikation der einzelnen Herzfehler
- Erfassung des Langzeit- Outcome ohne Intervention

Inzidenz angeborener Herzfehler – ca. 0,8-1,1%*

Herzfehler	Inzidenz	Mortalität im ersten Lebensjahr
VSD	30%	20-30%
ASD	ca. 8%	0,6%
Coarctation	5-8%	15%
PDA	10%	20%
TGA	3-7%	90%
Fallot´s-Tetralogy	5-10%	30%
TAPVD	2-3%	80%
AVSD	2-4%	bis 80%
Single ventricle	2-3%	50-60%
HLHS	< 1%	100%
Truncus arteriosus	0,5-1%	80-90%

UNIVERSITÄTS-
KINDERSPITAL
ZÜRICH

*A. Lindinger, G. Schwedler, H-W. Hense: Prevalence of Congenital Heart Defects in Newborns in Germany: Results of the First Registration Year of the PAN Study. Klin Pädiatr 2010; 222:1-10

Chirurgische Behandlungsprinzipien

- **biventrikuläre Korrektur (Primärziel!)**
  - Zweikammerherz anatomisch
  - Zweikammerherz physiologisch (Senning/ccTGA)
- **Palliationen**
  - Banding
  - Septektomie
  - Shunt
- **stufenweise Korrektur**
  - vorherige vorbereitende Operation (Banding / Shunt)
  - anschliessende Korrektur mit niedrigerem Risiko

Behandlungswege – Methoden und Ziele

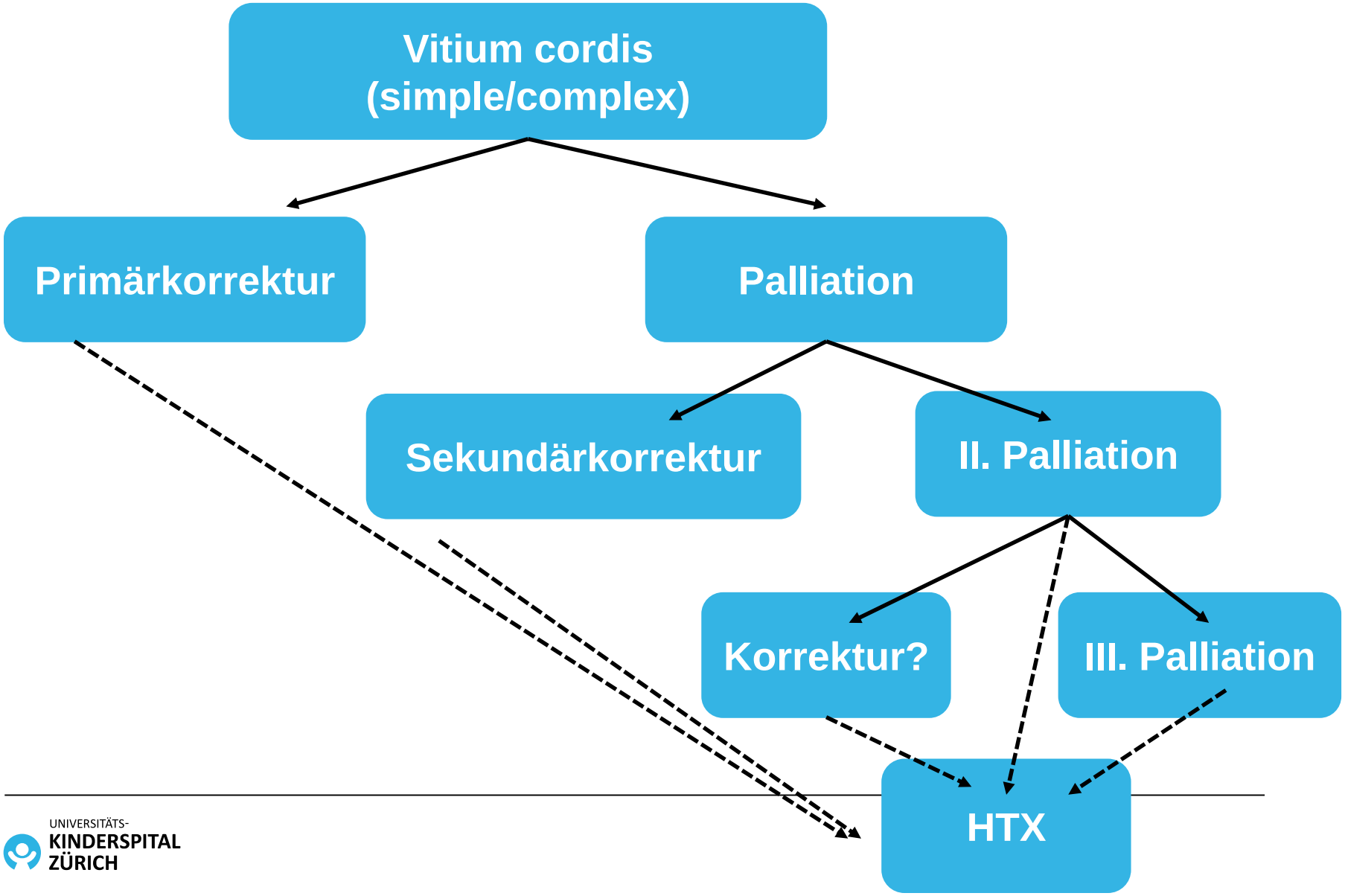

Operative Technik - Herzlungenmaschine

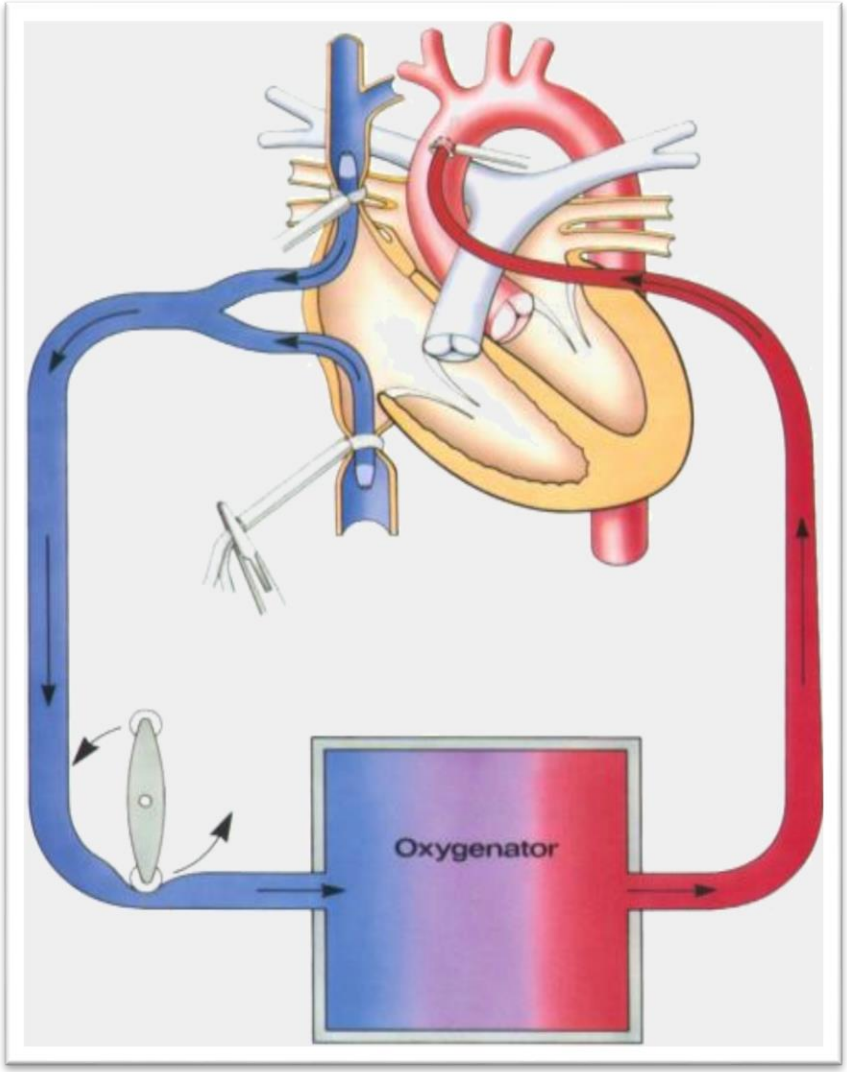

- Invasivität
- Hämodilution
- Hypothermie
- Myokardprotektion (Kardioplegie)
- generelle Organprotektion (selektive Perfusion)

Wachstum und Entwicklung

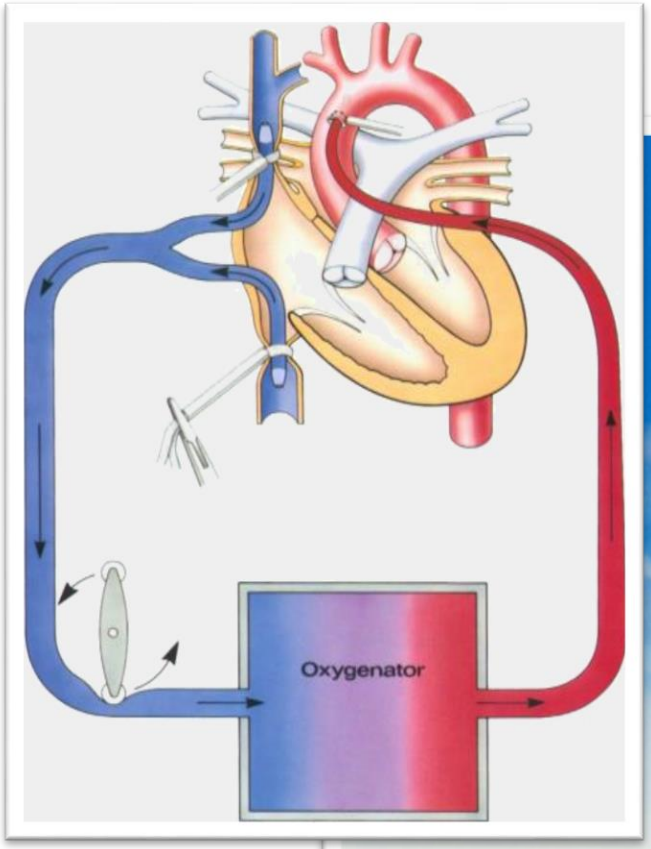

Historie - Palliation - Shunt

Helen TAUSSIG

Alfred BLALOCK

Alan Rickman
Mos Def
SOMETHING THE LORD MADE
SUNDAY, MAY 30, 9PM
HBO

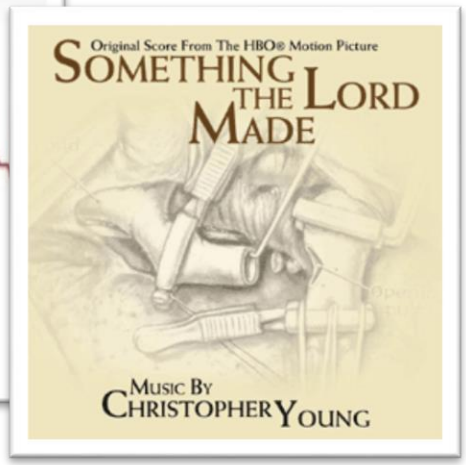
Original Score From The HBO® Motion Picture
SOMETHING THE LORD MADE
MUSIC BY CHRISTOPHER YOUNG

Palliative Shuntanlagen
- Zyanose und Einkammerherzen

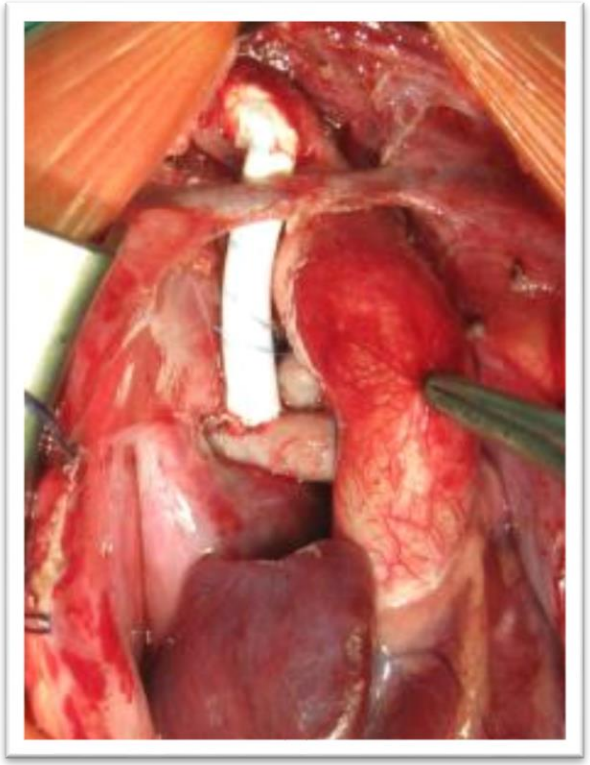

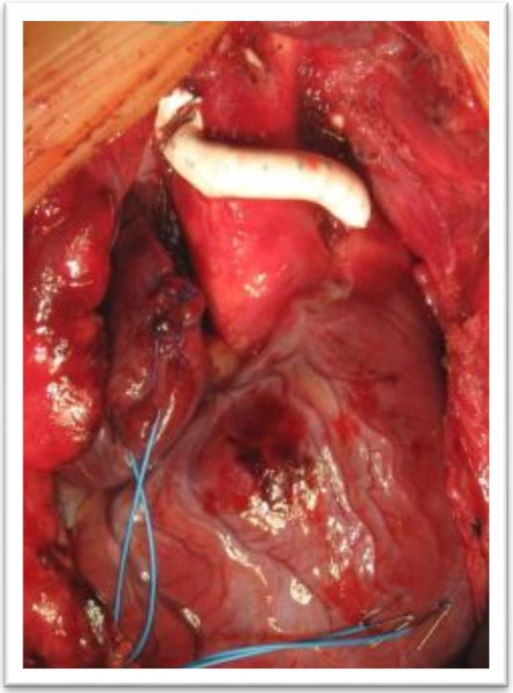

- zentral:
  - Aorta → PA Stamm
  - Tr. Brachioceph. → PA Stamm
- M-BTS:
  - Tr. brachioceph. → RPA
- Waterston/Pott (direkt):
  - Ao. Asc. → RPA / Ao.desc. → LPA

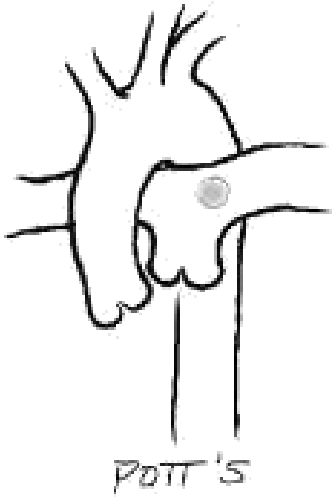

Pulmonalarterienbanding bei PHT

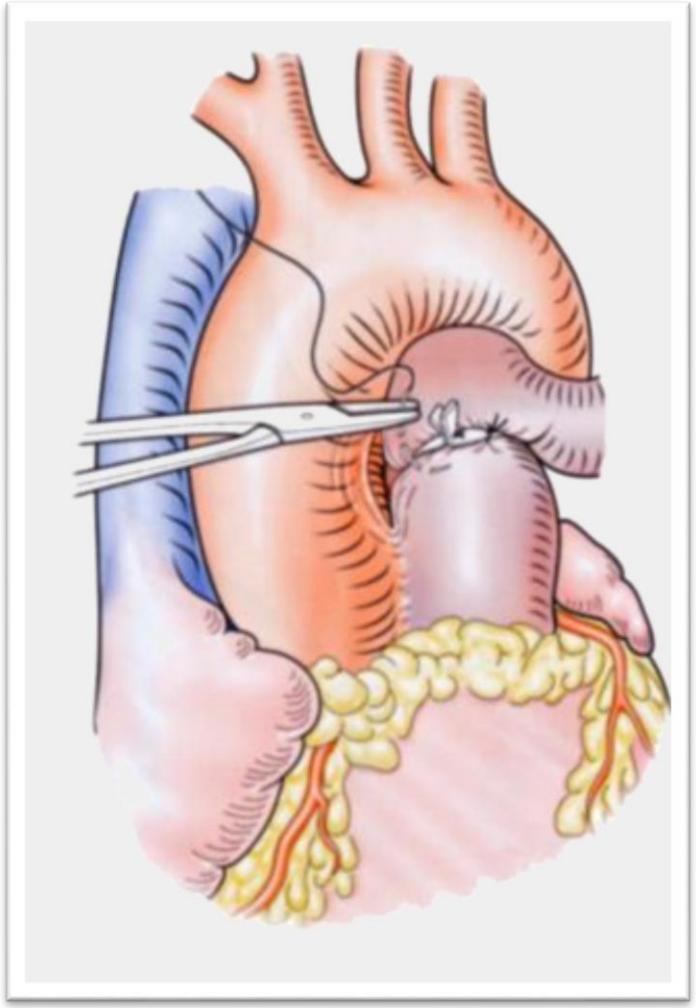

- mediane Sternotomie
- Drosseln des PA-Stamms
- VSD, AVSD ...
- Einkammerherzen

Walton Lillehei - Crosscirculation

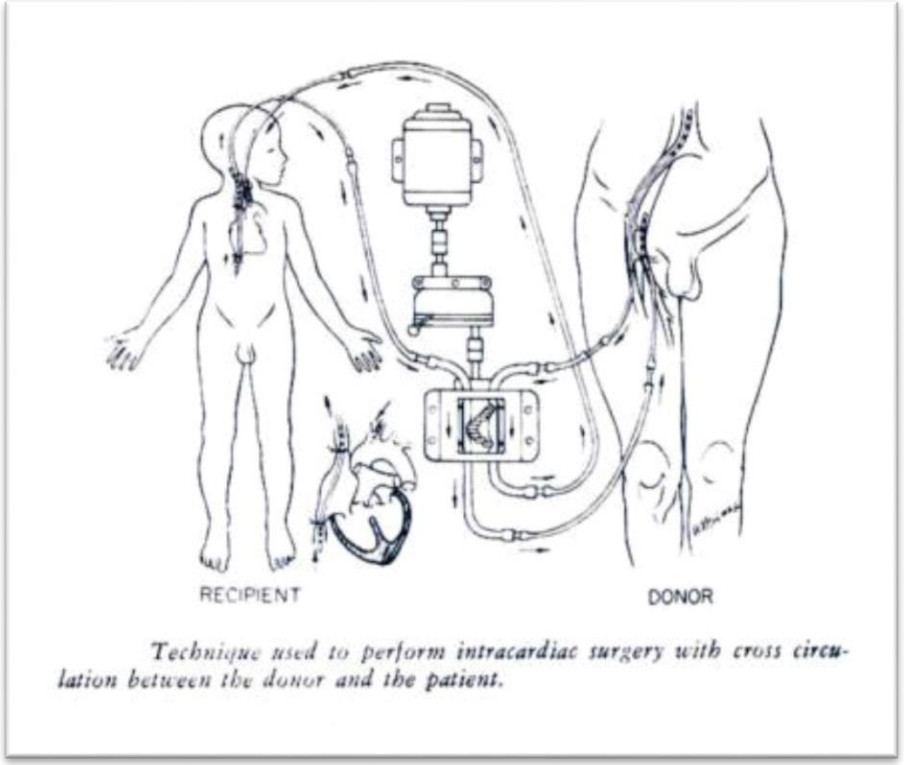

Technique used to perform intracardiac surgery with cross circulation between the donor and the patient.

1954: VSD
1955: Fallot Korrektur

aber 200%-ige Mortalität?

Courtesy to St. Jude and Walton C. Lillehei

Fallot - transventrikulärer VSD-Verschluss

- RVOT-Rekonstruktion

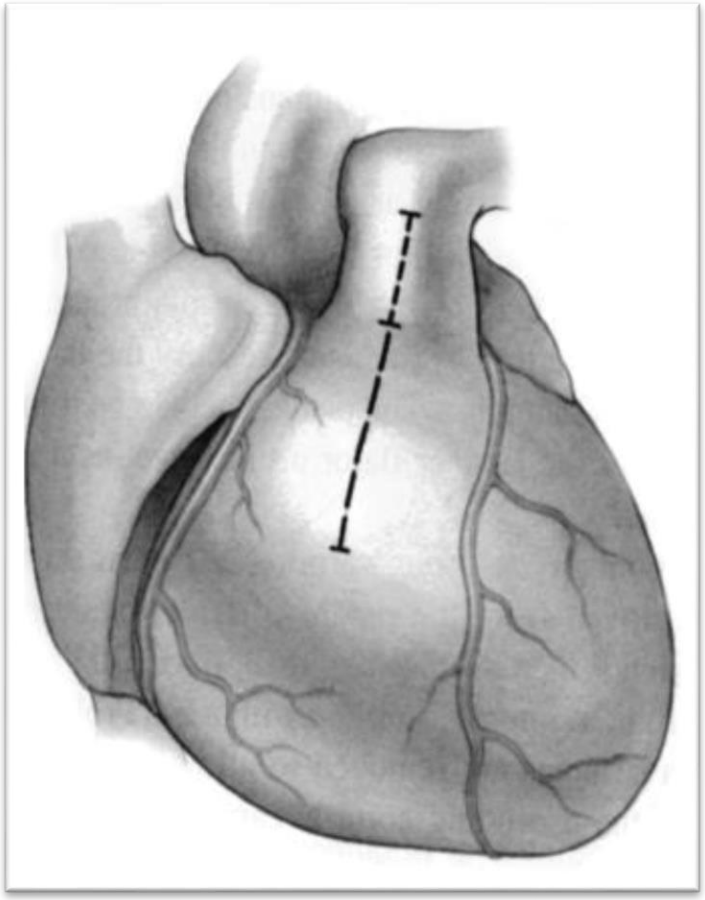

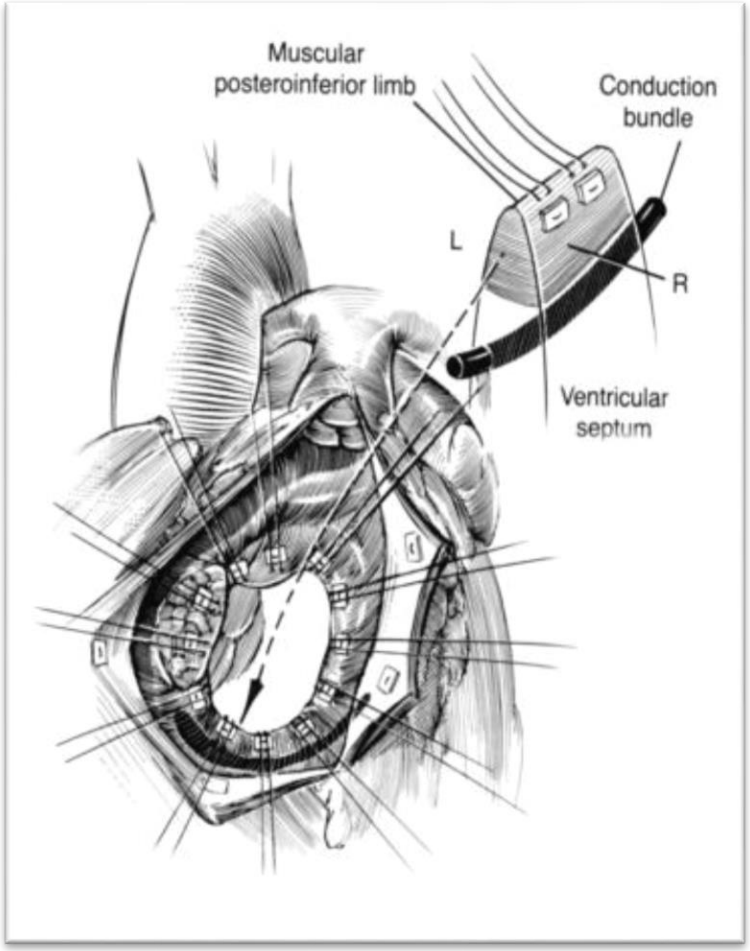

VSD-Verschluss vom Vorhof aus (transatrial)

- Erhalt der Trikuspidalklappe

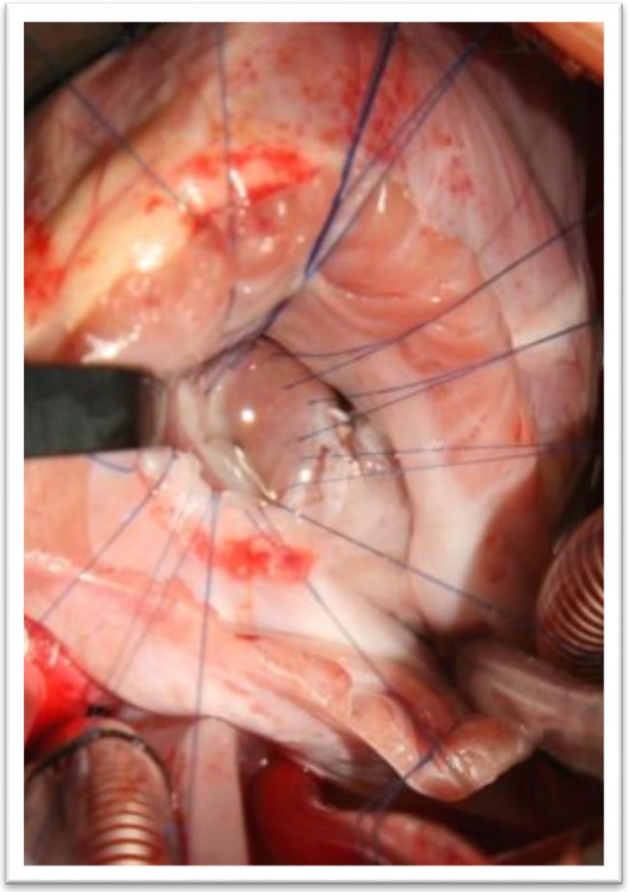

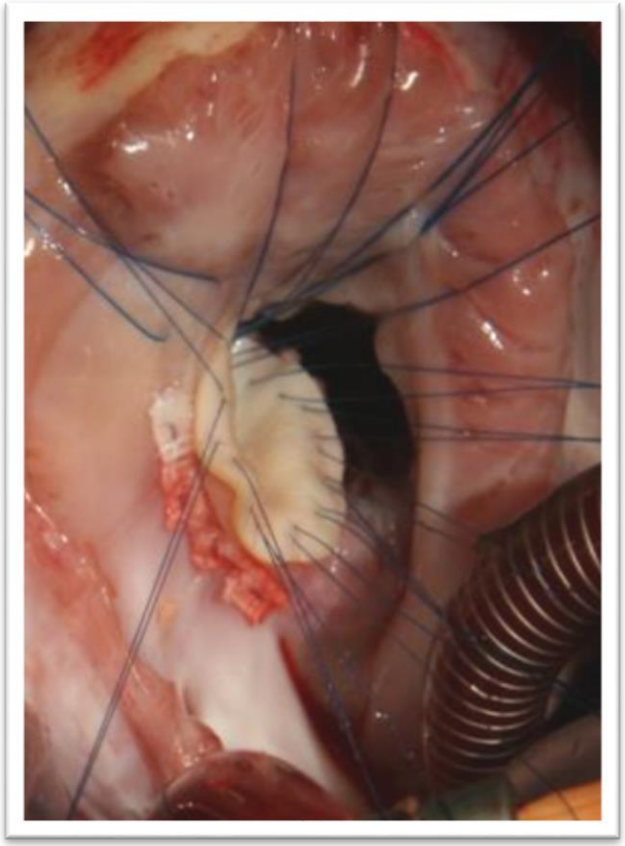

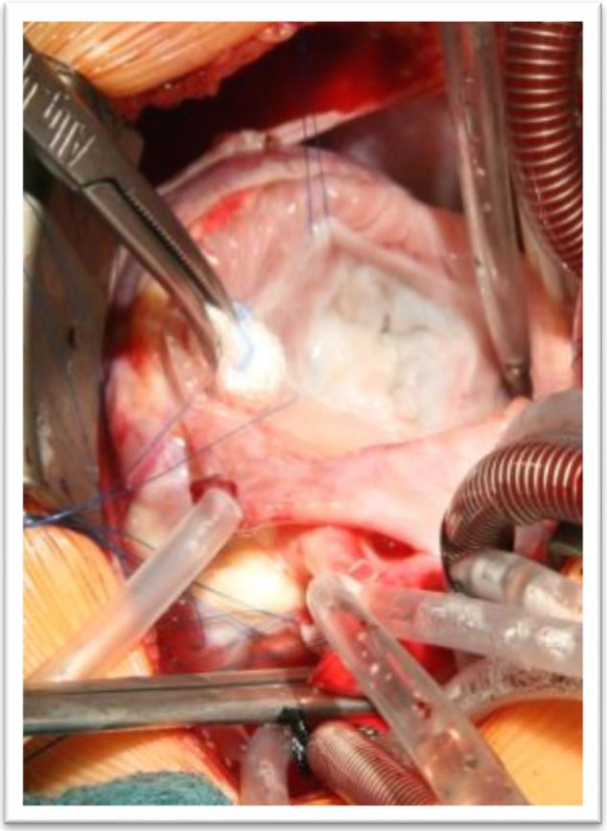

transanuläre RVOT-Eröffnung

- Pulmonalklappen-Hypoplasie

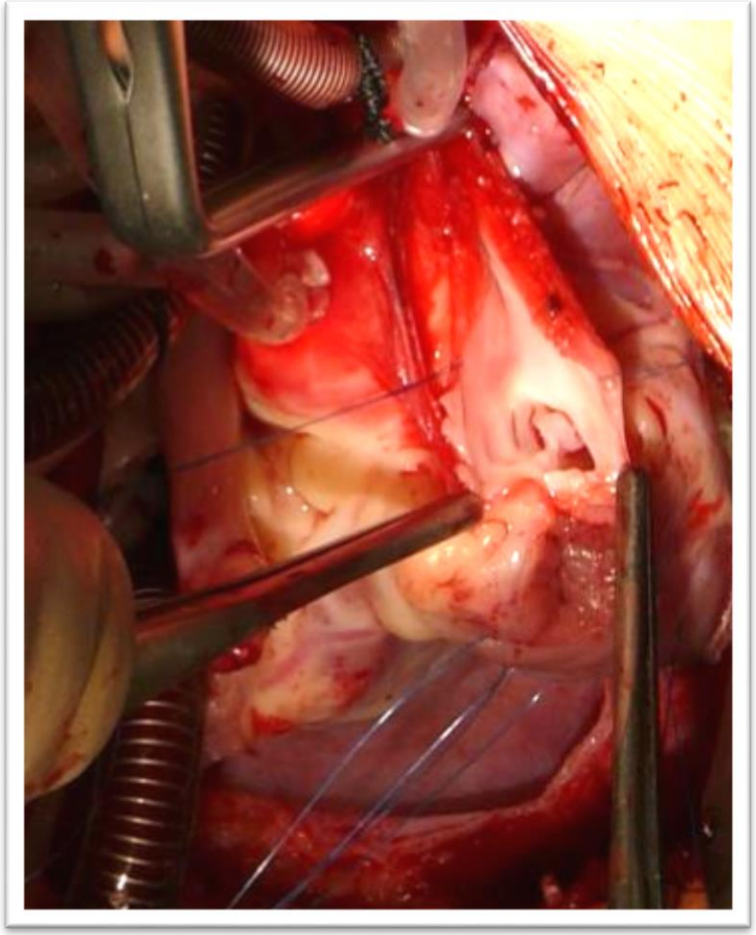

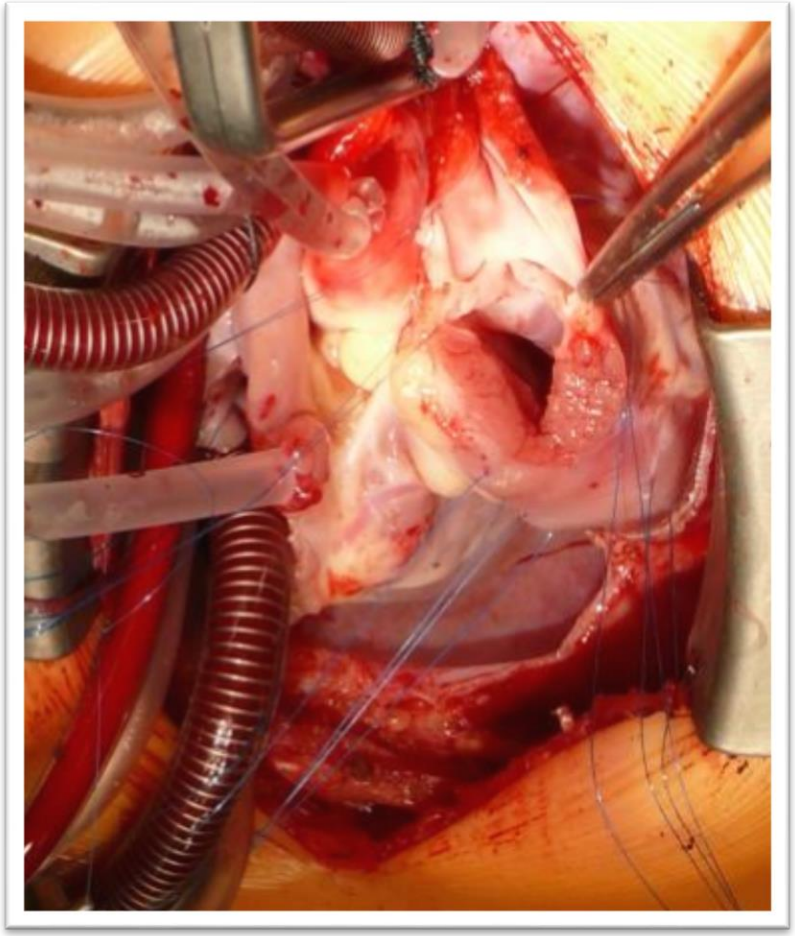

RVOT-Rekonstruktion

RVOT-Rekonstruktion-PK-Erhalt

transanulärer-RVOT-Patch

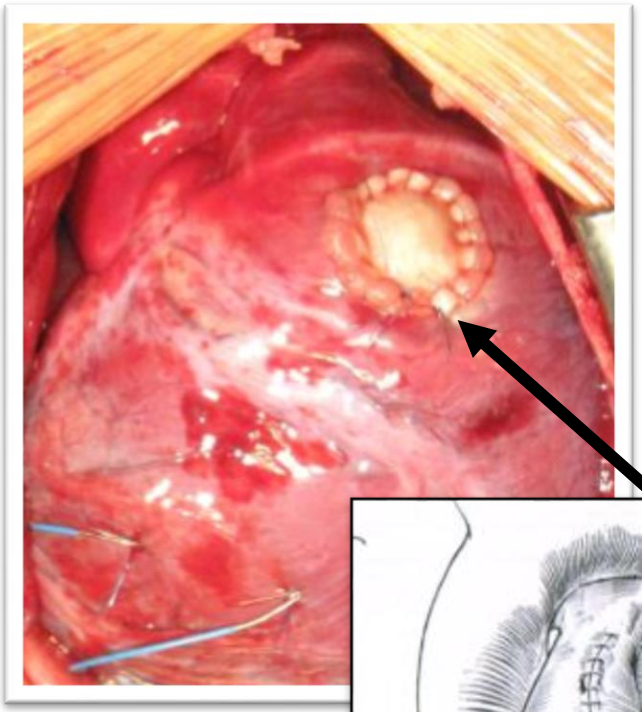

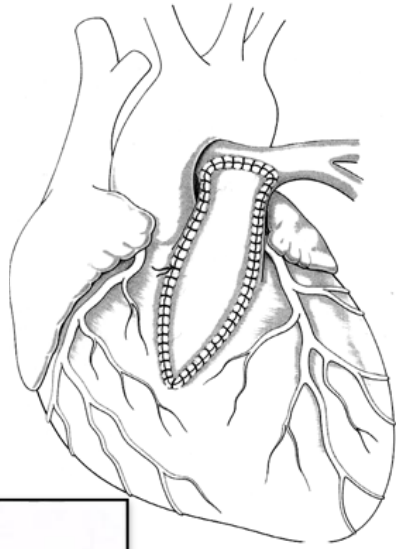

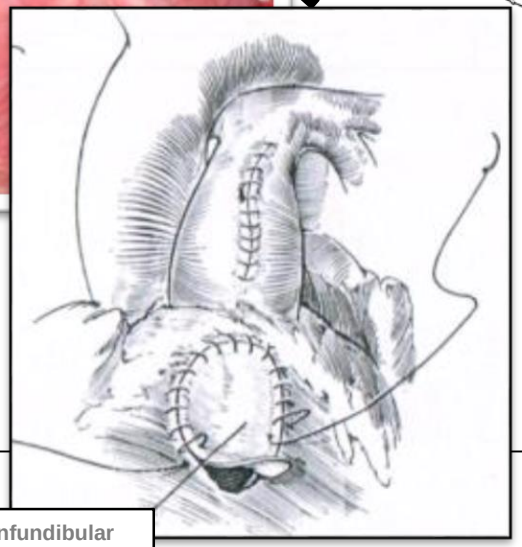

Infundibular Patch

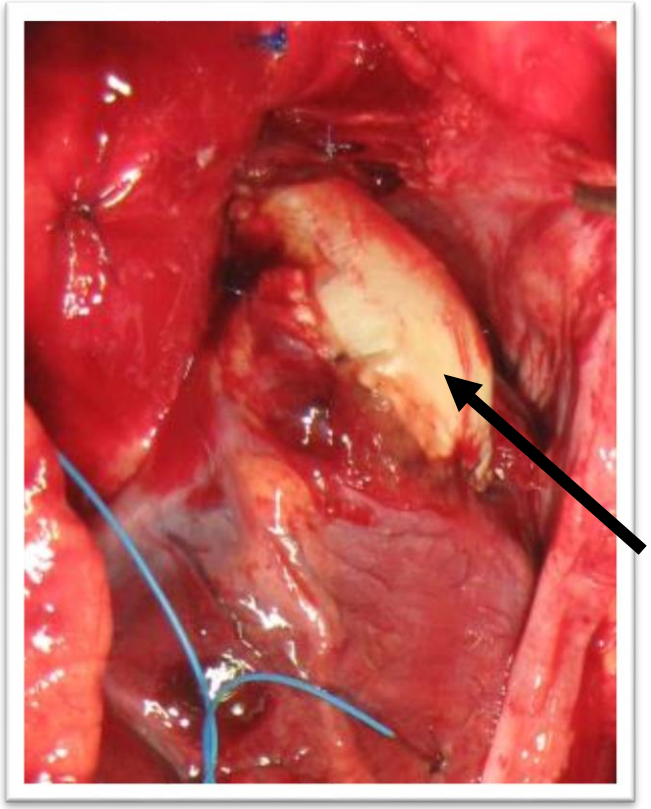

Behandlungserfolge (ECHSA-Database)

- mehr als 325.000 dokumentierte Operationen

Vitium	**Letalität 1. Lebensjahr**	**OP-Risiko Europa**
Ventrikelseptumdefekt (VSD)	20-30%	0,7 %
Vorhofseptumdefekt (ASD)	0,6%	0,3 %
Aortenisthmusstenose (ISTA)	15%	2,2 %
Persistierender Ductus Botalli (PDA)	20%	2,1 %
TGA (IVS bzw. mit VSD)	90%	5,6 % - 9,4%
Fallot-Tetralogie	30%	2,3 %
Totale Lungenvenenfehlmündung	80%	9,8 %
Kompletter AV-Kanal (CAVSD)	bis 80%	4,9 %
Univentrikuläres Herz (UVH)	50-60%	5-25%
Hypoplastisches Linksherzsyndrom	100%	23,6 %
Truncus arteriosus communis	80-90%	15,8%

Mortalitätsziffern für angeborene Herzfehler (AHF)

- Senkung um mehr als 75% seit 1980

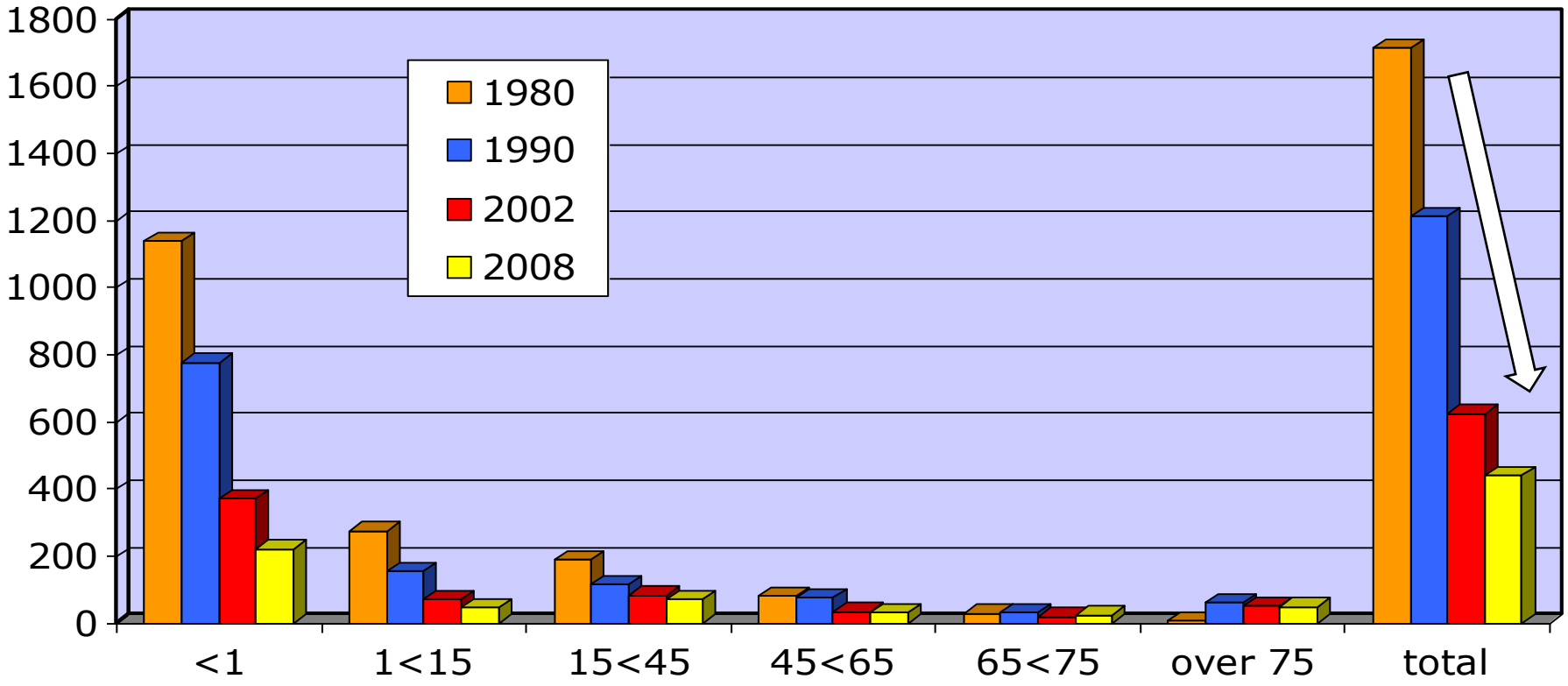

aus dem Bruckenberger „Herzbericht"

Entwicklung der Mortalitätsrate in der BRD

(Quelle: Deutscher Herzbericht 2020)

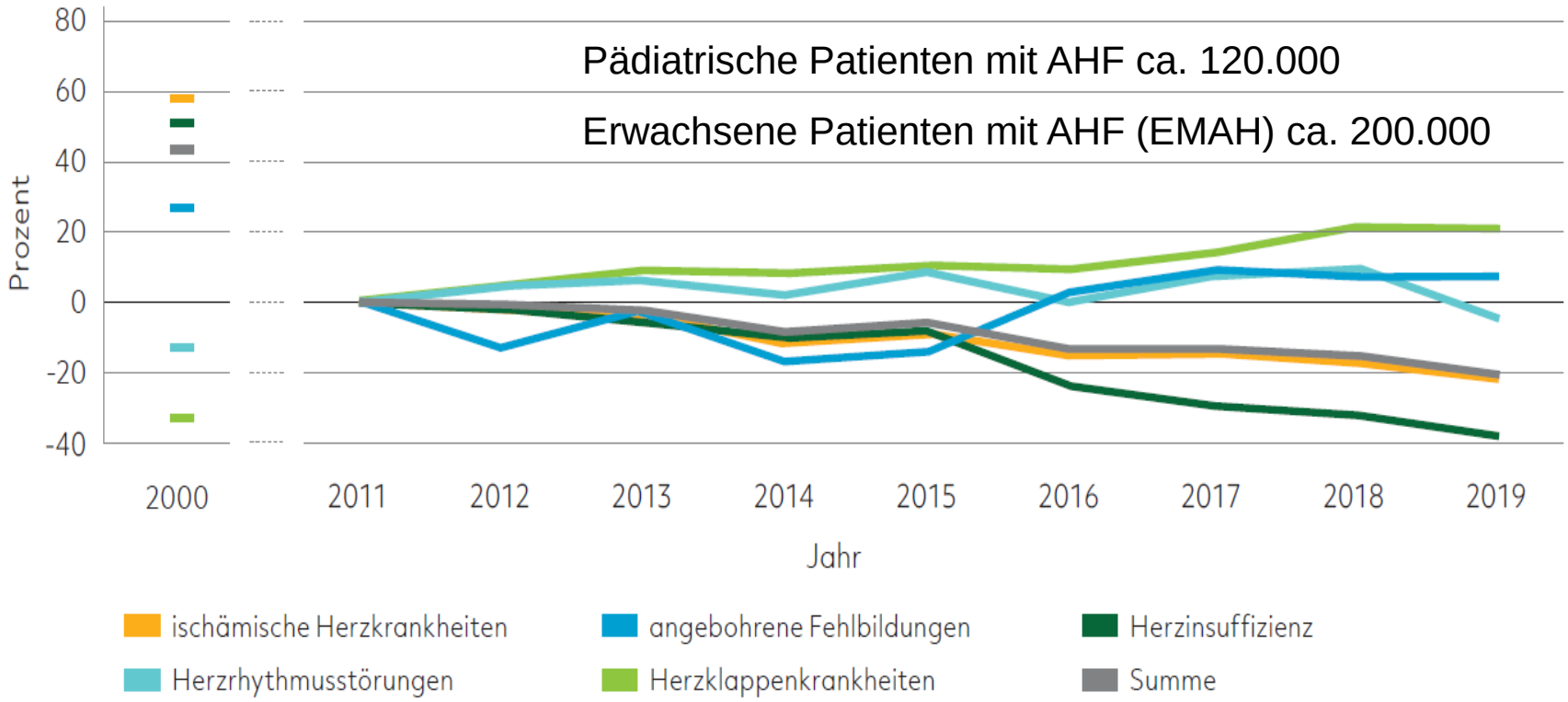

Für 2000 Bevölkerung auf der Grundlage des Zensus von 1987, ab 2011 Bevölkerung auf Grundlage des Zensus 2011
Berechnung auf Grundlage von Daten des Statistischen Bundesamtes

Shaun White



Shaun White – patient history

- geboren am 3.9.1986
- Fallot'sche Tetralogie
- Operationen (2 oder 3 … ?)
  - Shunt
  - Korrekturopertion
  - Conduit (?)
- Goldmedaillengewinner in der Half-Pipe

  2006, 2010 und 2018



Wann ist es wirklich eine Korrektur?

- anatomische Zwei-Kammerkorrektur
- Reoperationsfreiheit
- keine wachstumshemmende Implantate
- normale Herzleistung

ELSEVIER

European Journal of Cardio-thoracic Surgery 20 (2001) 1207–1213

EUROPEAN JOURNAL OF
CARDIO-THORACIC
SURGERY

www.elsevier.com/locate/ejcts

Results of biventricular repair of congenital cardiac malformations: definitive corrective surgery?☆

Rüdiger Lange[a,*], Christian Schreiber[a], Thomas Günther[a], Michael Wottke[a], Felix Haas[a], Franz Meisner[a], John Hess[b], Klaus Holper[a]

[a]*Department of Cardiovascular Surgery, German Heart Center Munich at the Technical University Munich, Munich, Germany*
[b]*Department of Paediatric Cardiology, German Heart Center Munich at the Technical University Munich, Munich, Germany*

Septumdefekte – VSD-Patchverschluss

Wann ist es wirklich eine Korrektur?

Vitium	anatomische Korrektur	niedrige ReOP-Rate	Herz-Fx normal	Conduits
Ventrikelseptumdefekt (VSD)	✓	✓	✓	-
Vorhofseptumdefekt (ASD)	✓	✓	✓	-
Aortenisthmusstenose (ISTA)	✓	✓	✓	-
Persistierender Ductus Botalli (PDA)	✓	✓	✓	-
TGA	✓	**5%**	✓	-
Fallot-Tetralogie	✓	-	✓	±
Totale Lungenvenenfehlmündung	✓	**5-10%**	✓	-
Kompletter AV-Kanal (CAVSD)	✓	**5-10%**	✓	-
Univentrikuläres Herz (UVH)	-	-	-	±
Hypoplastisches Linksherzsyndrom	-	-	-	-
Truncus arteriosus communis	✓	**100%**	✓	+

TGA – anatomische Korrektur bei Neonaten

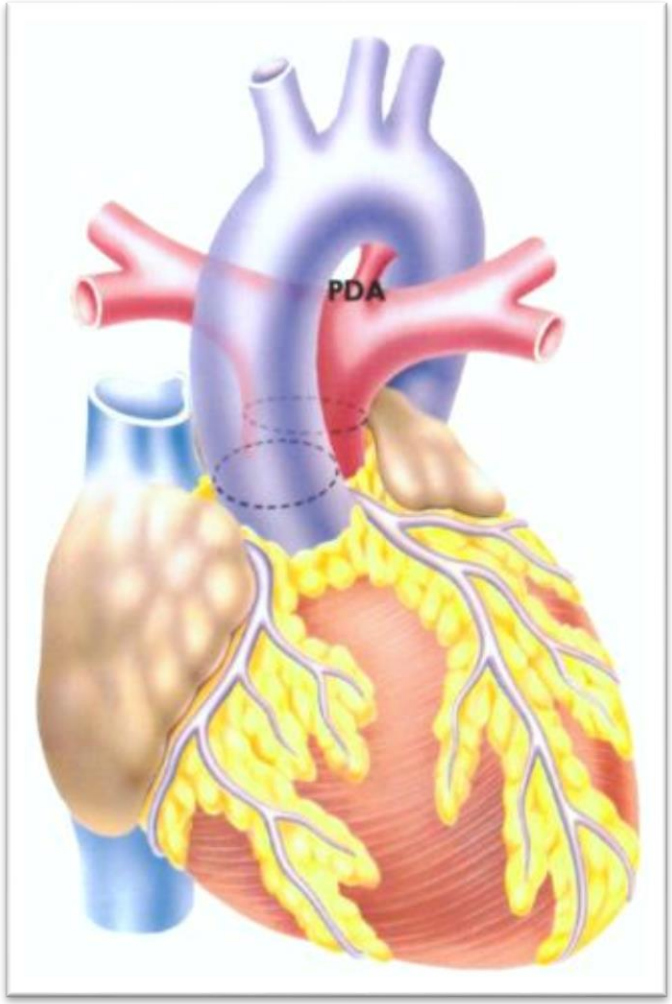

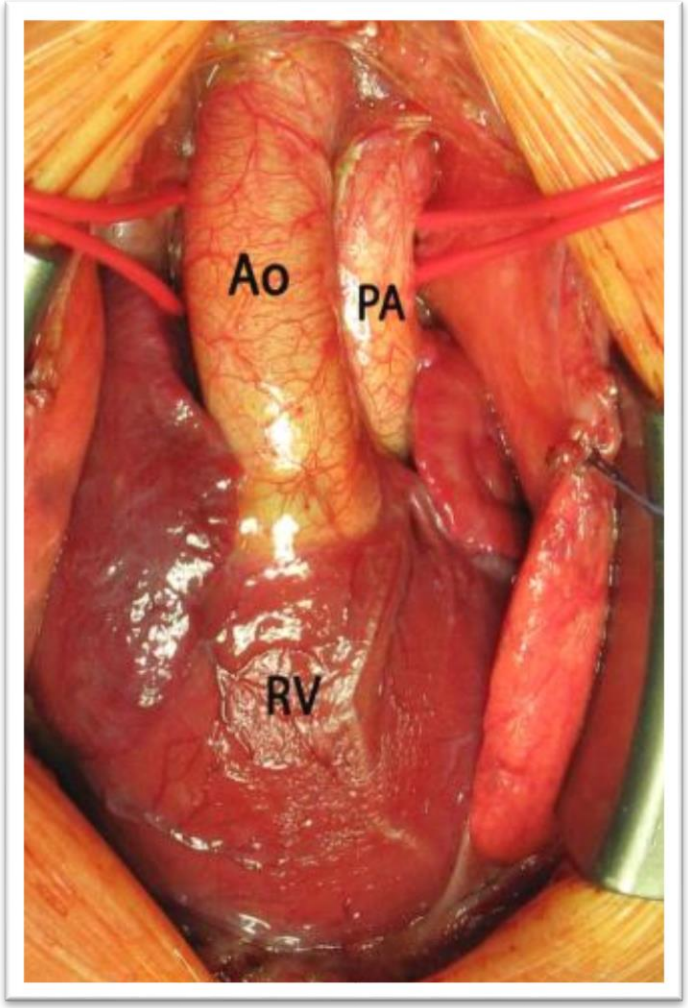

Koronartransfer

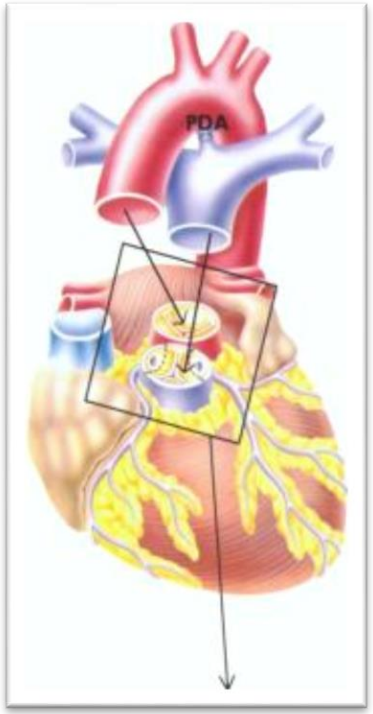

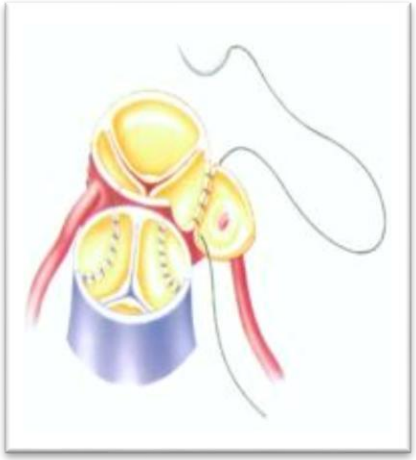

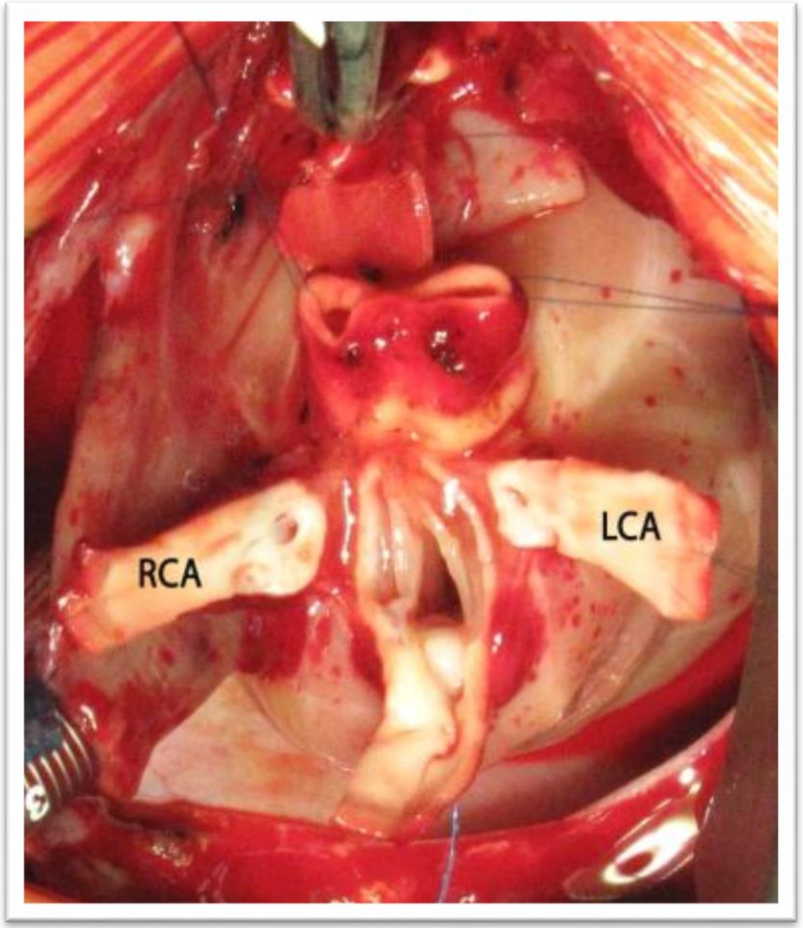

Umsetzen der Gefässe - Lecompte-Manöver

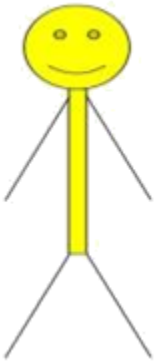

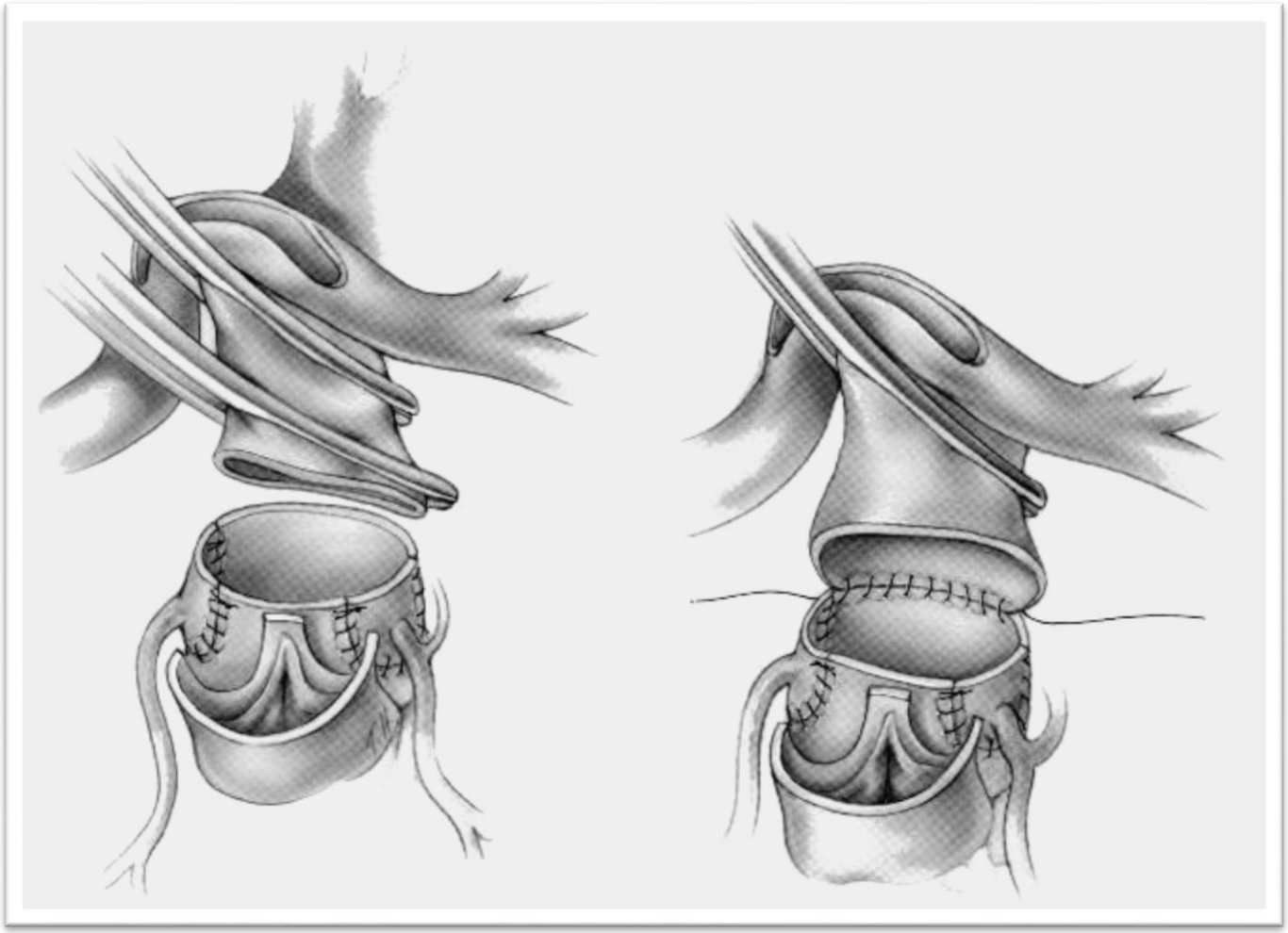

Koronartransfer – Qualitätskontrolle

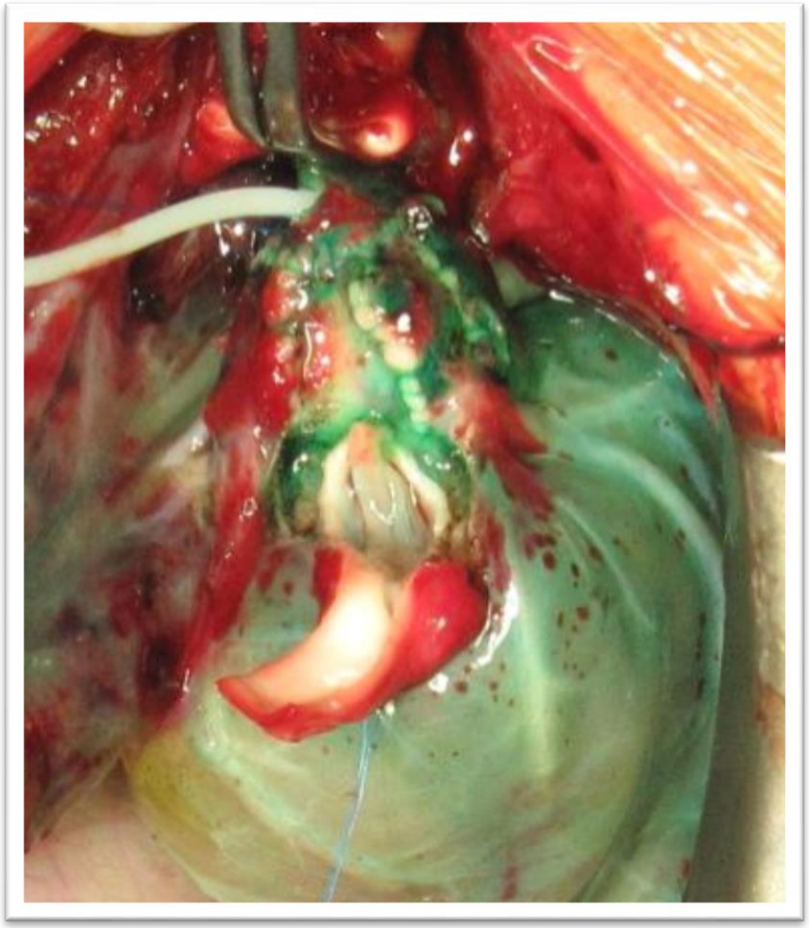

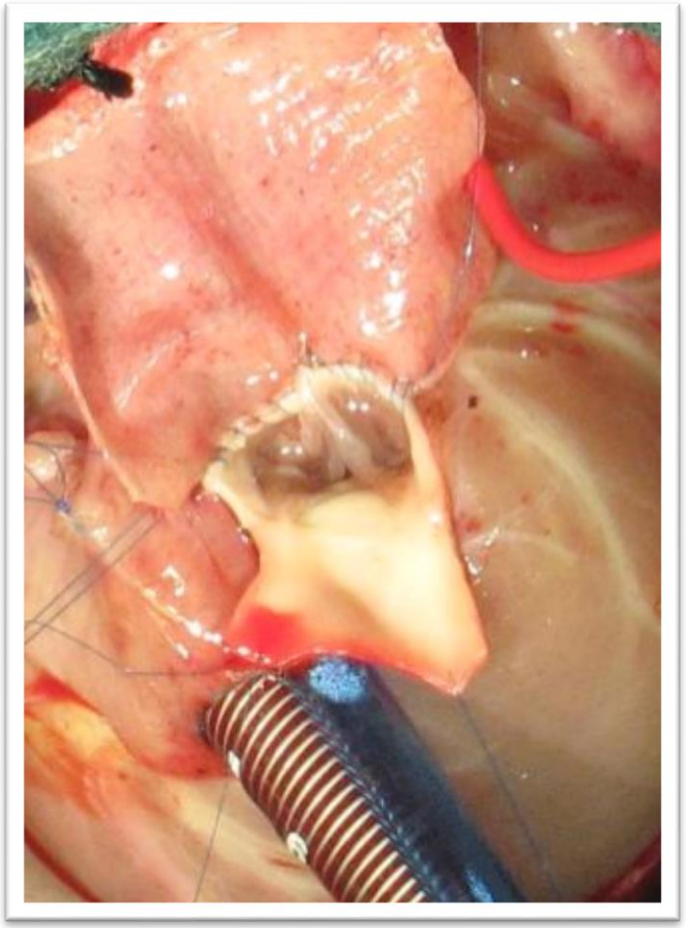

Neo-Pulmonalis-Rekonstruktion

- TGA/IVS Ergebnisse nach Switch

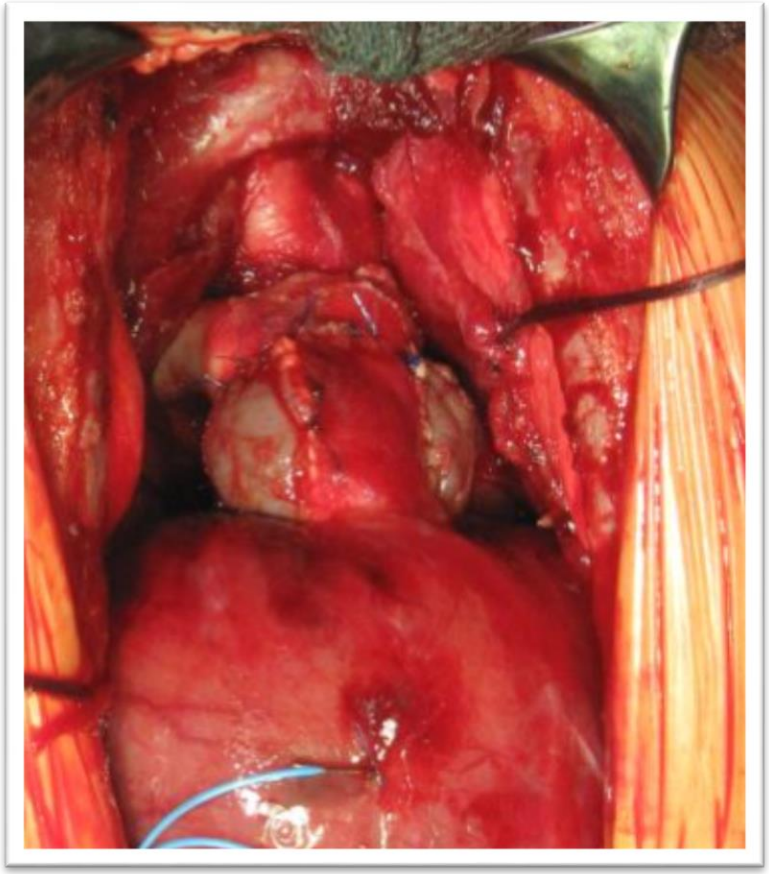

- Letalität 1,5%
- herzgesunde Kinder
- normale Lebenserwartung
- Reoperationen selten

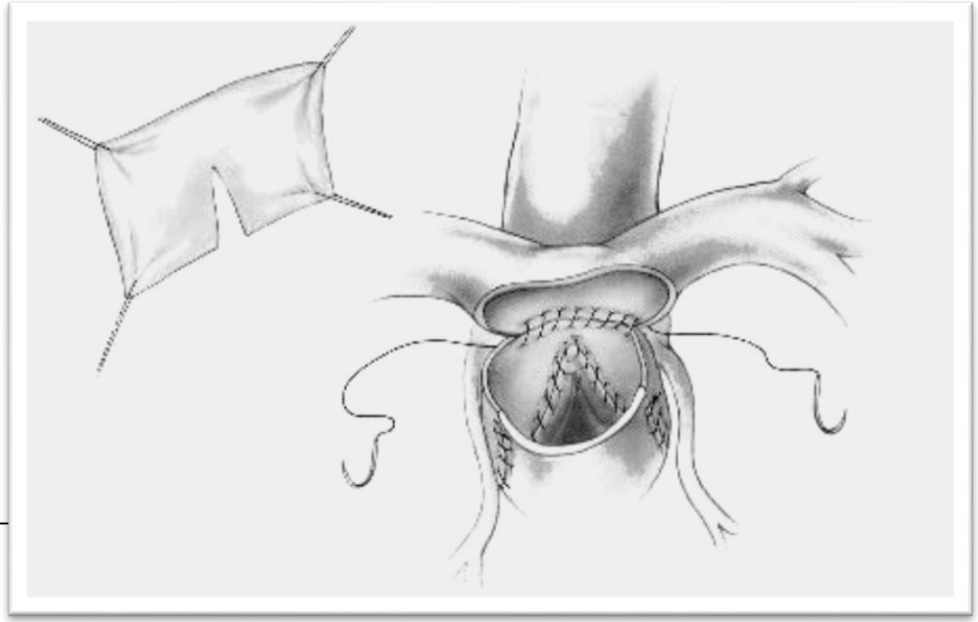

Ergebnisse der arteriellen Switchoperation

- Mortalität (0.5-4% bei unkomplizierter TGA)
- Mortalität (5-12% bei komplexer TGA)
- Reoperationen (selten) – supravalvuläre Pulmonalstenose (3-10%)

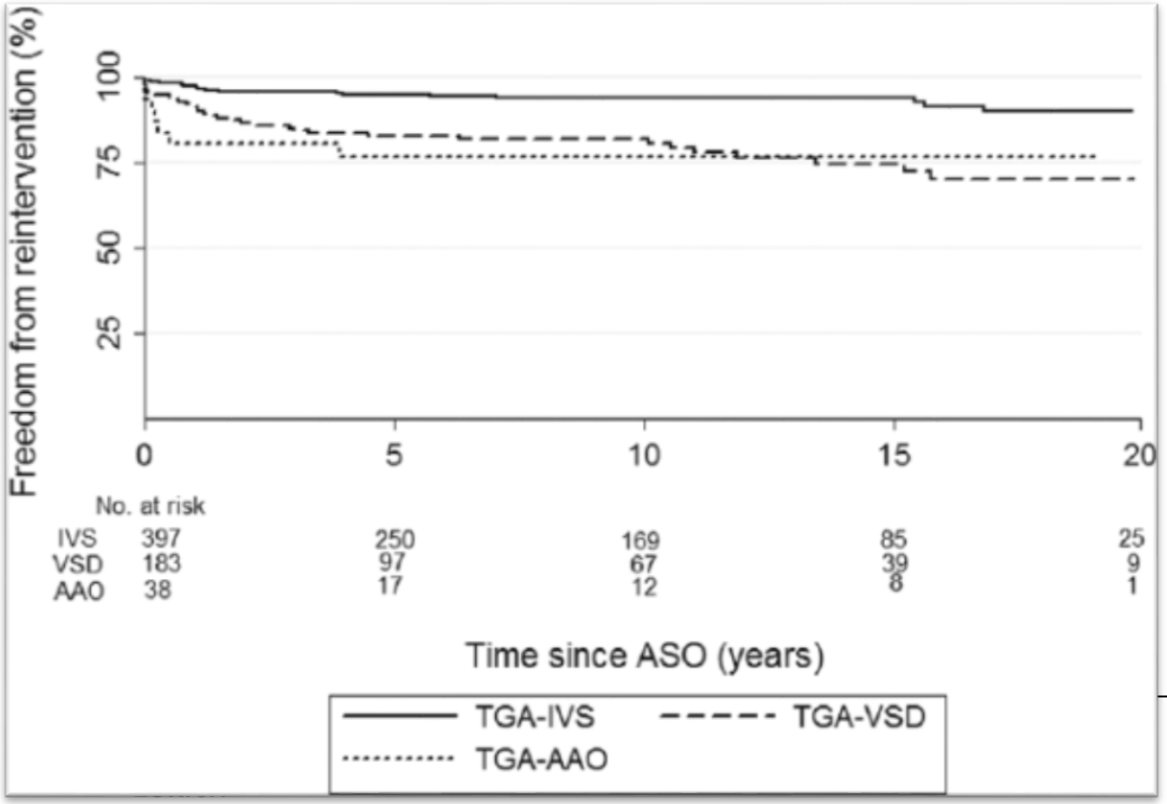

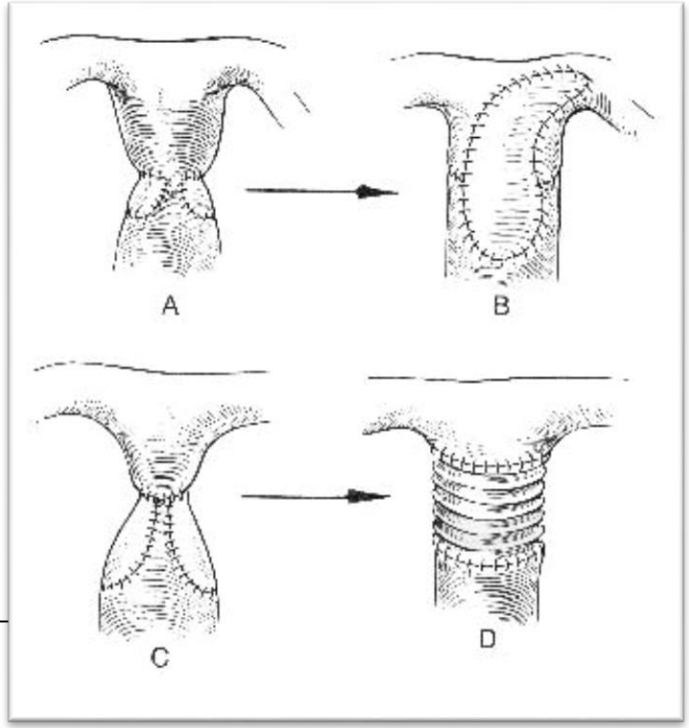

Problem der defekten Herzklappen

- Aortenklappenrekonstruktion – Präop Echo

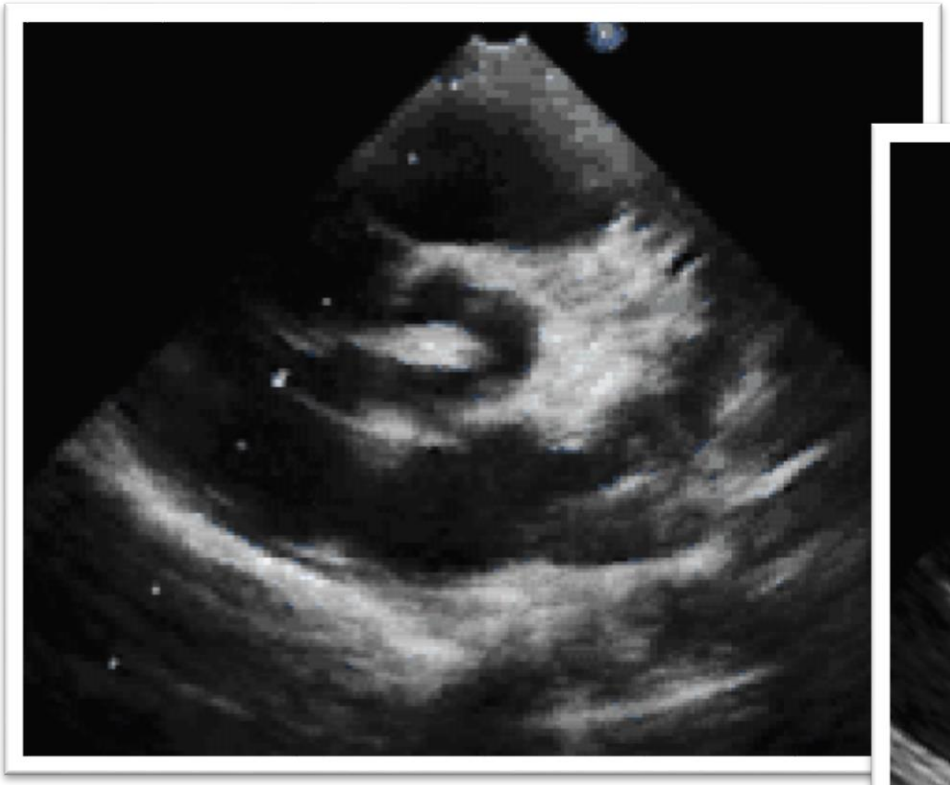

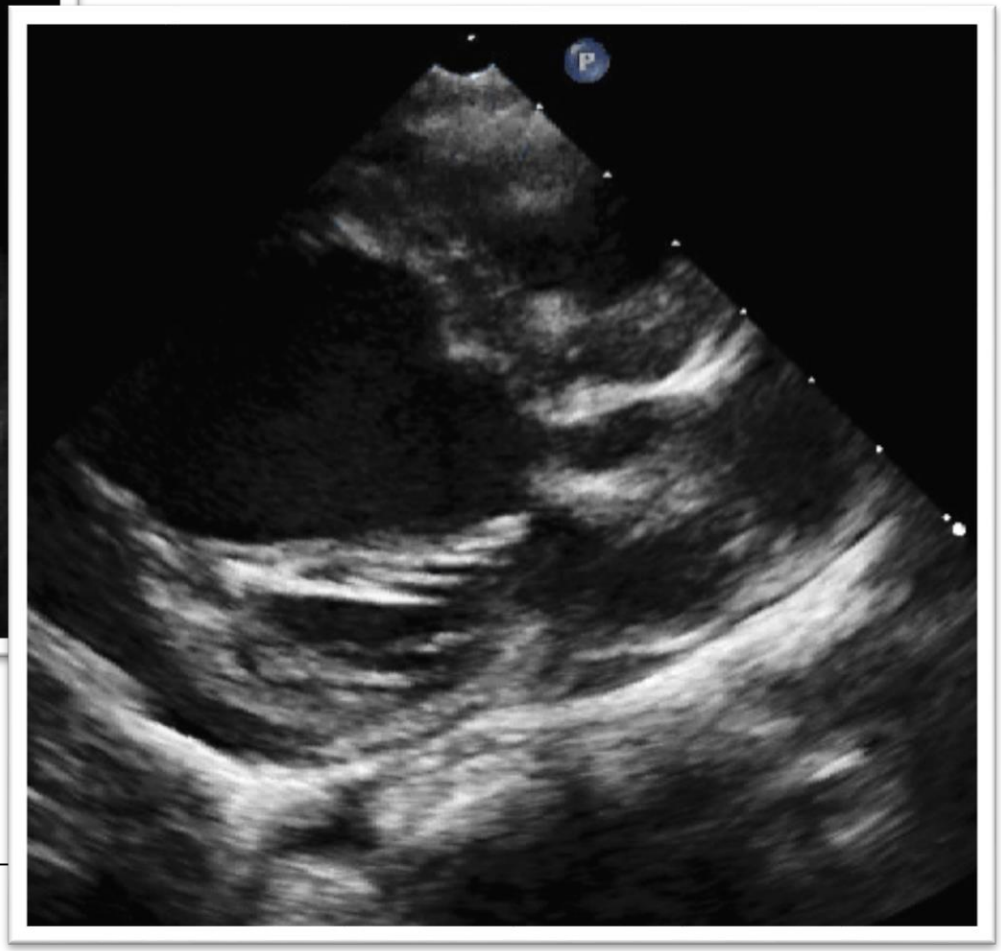

Problem der defekten Herzklappen

-Trikuspidalisierung einer unikuspiden Klappe

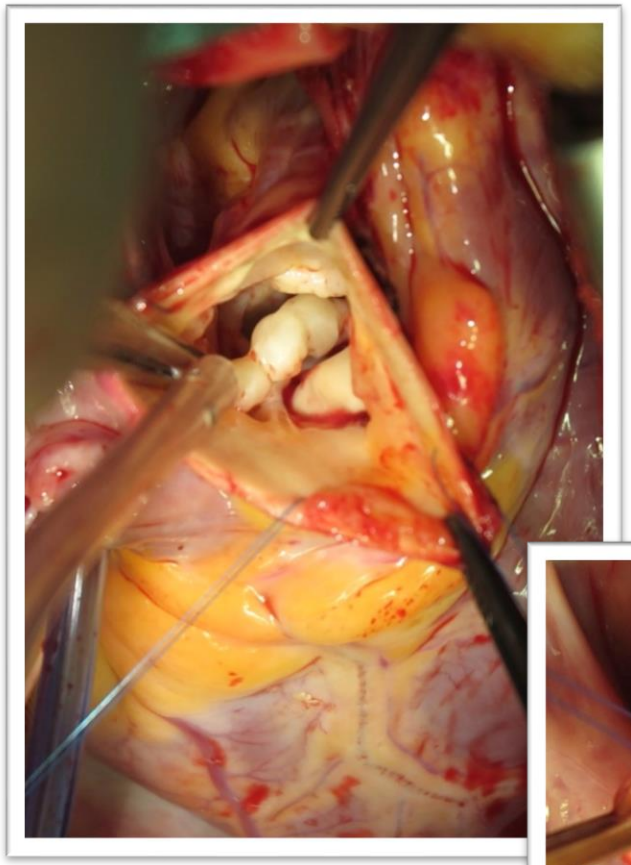

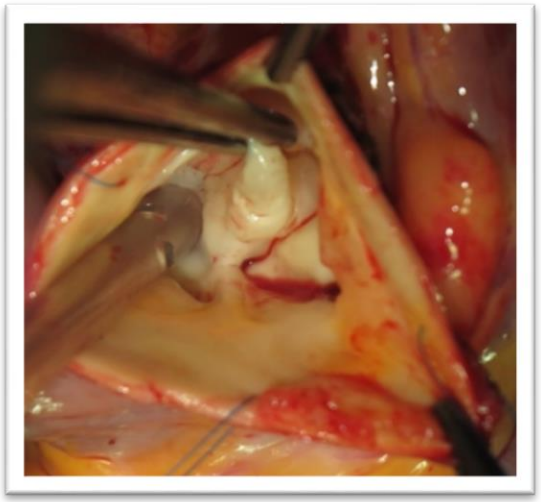

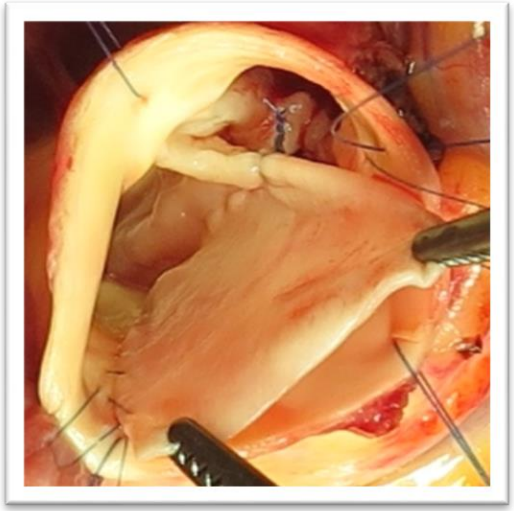

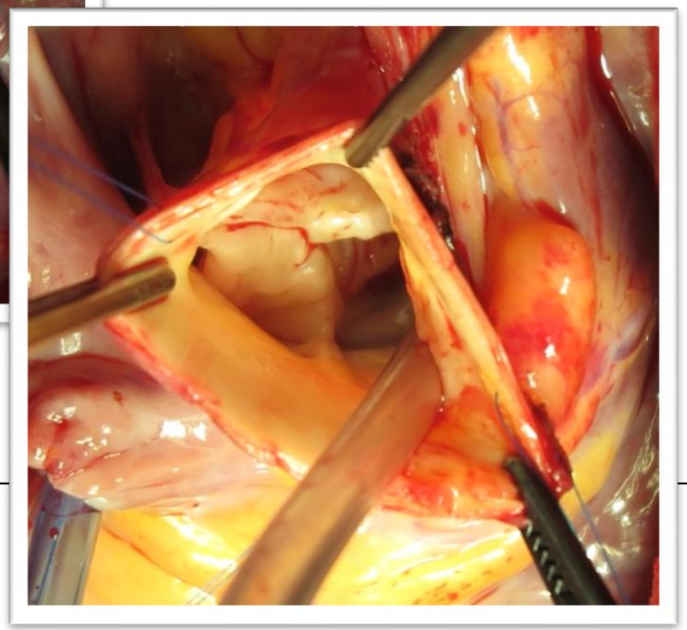

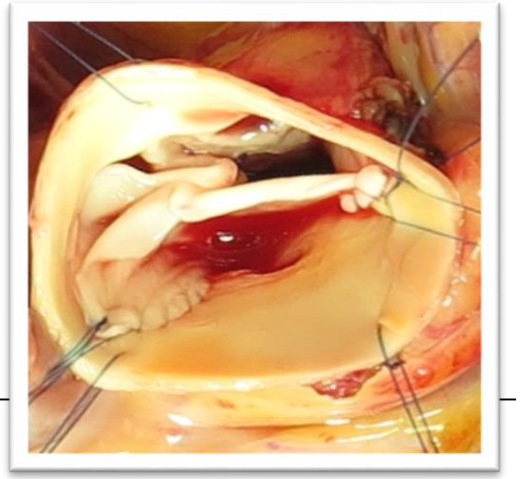

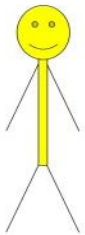

Problem der defekten Herzklappen

- Nachuntersuchung - Ultraschall 2,5 Jahre postop

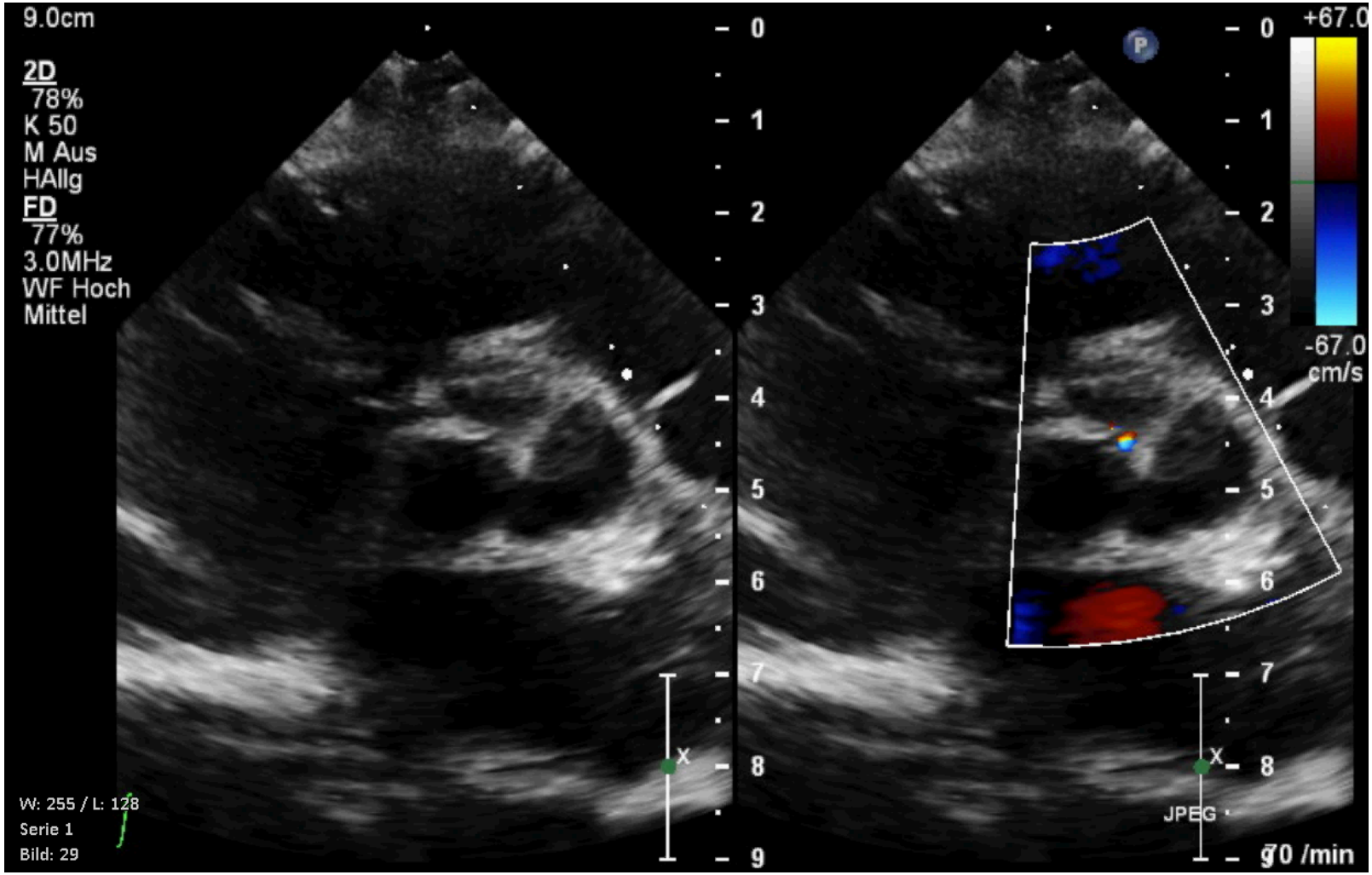

Problem der defekten Herzklappen – Klappersatz?

- mitwachsend … ???

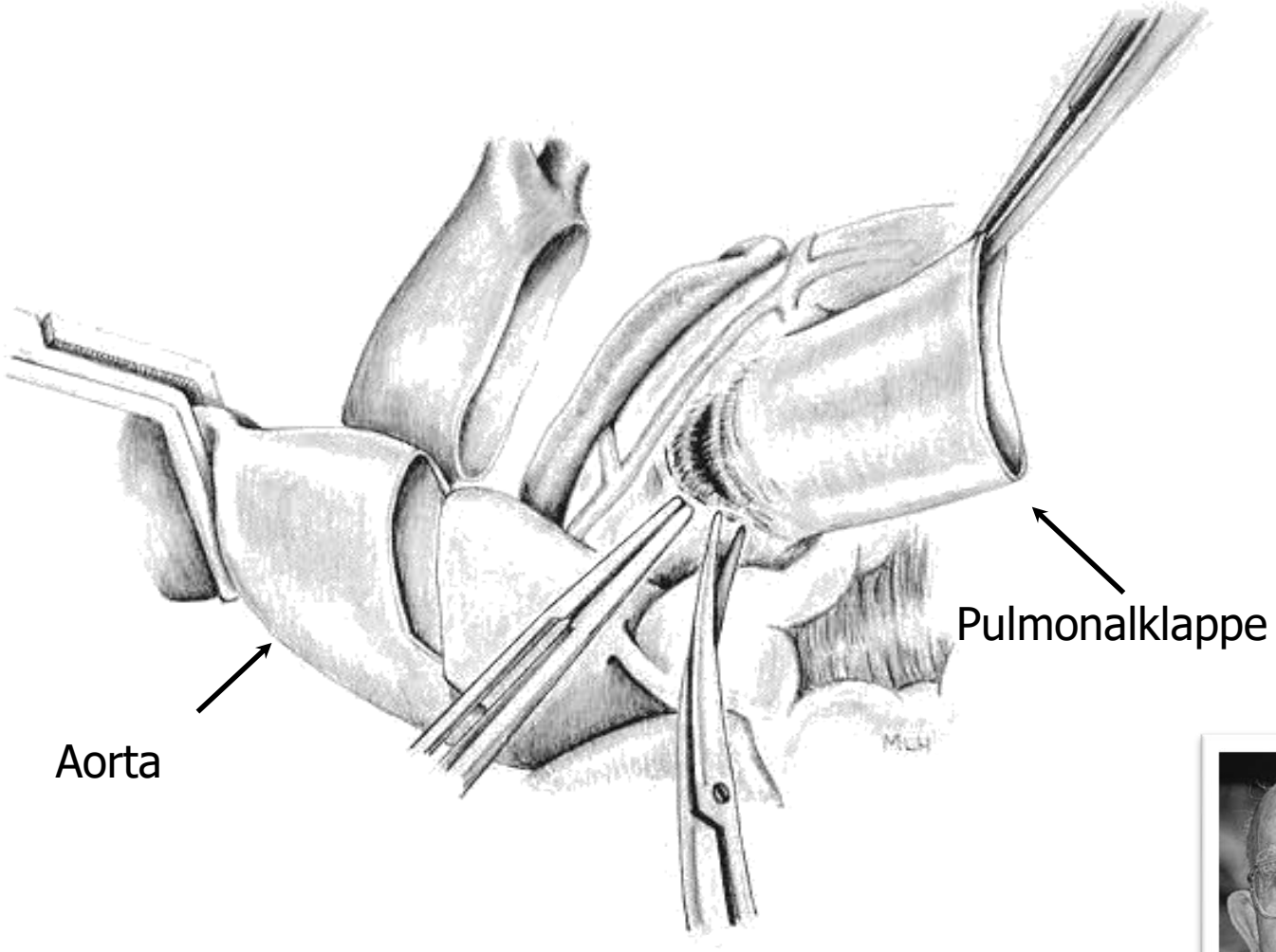



Ross-Operation in Mini-Root-Technik

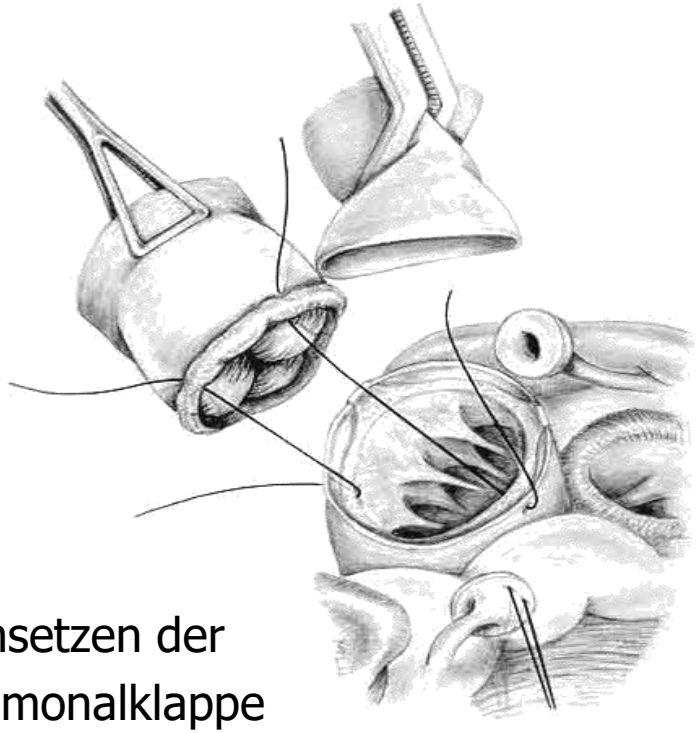

Umsetzen der
Pulmonalklappe
in Aortenposition

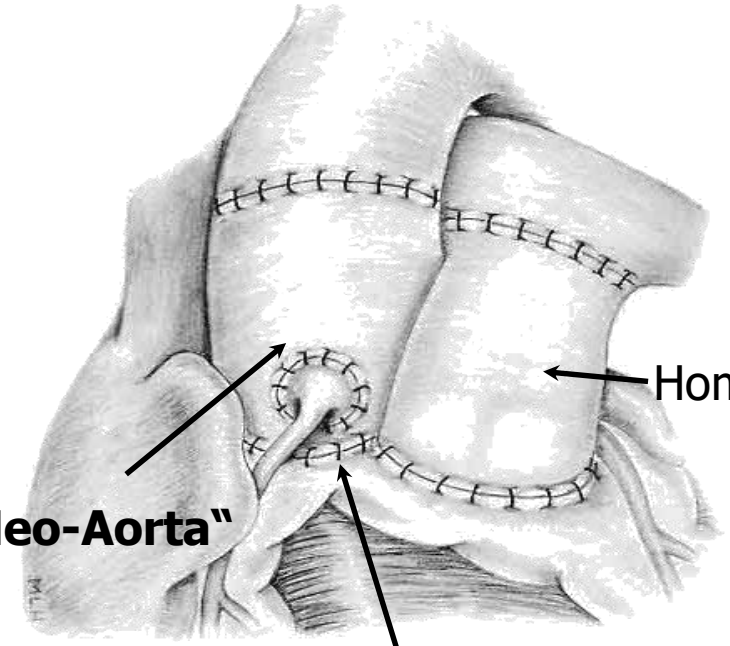

Ross Operationen – Langzeitergebnisse

- Reoperationen am Auto- und Homograft*

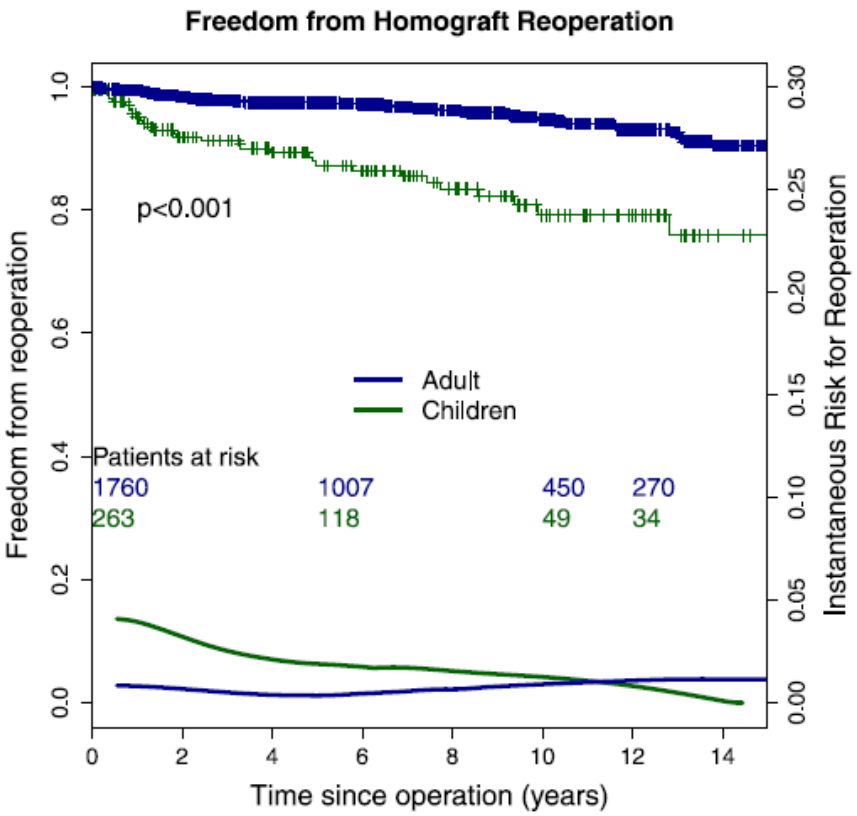

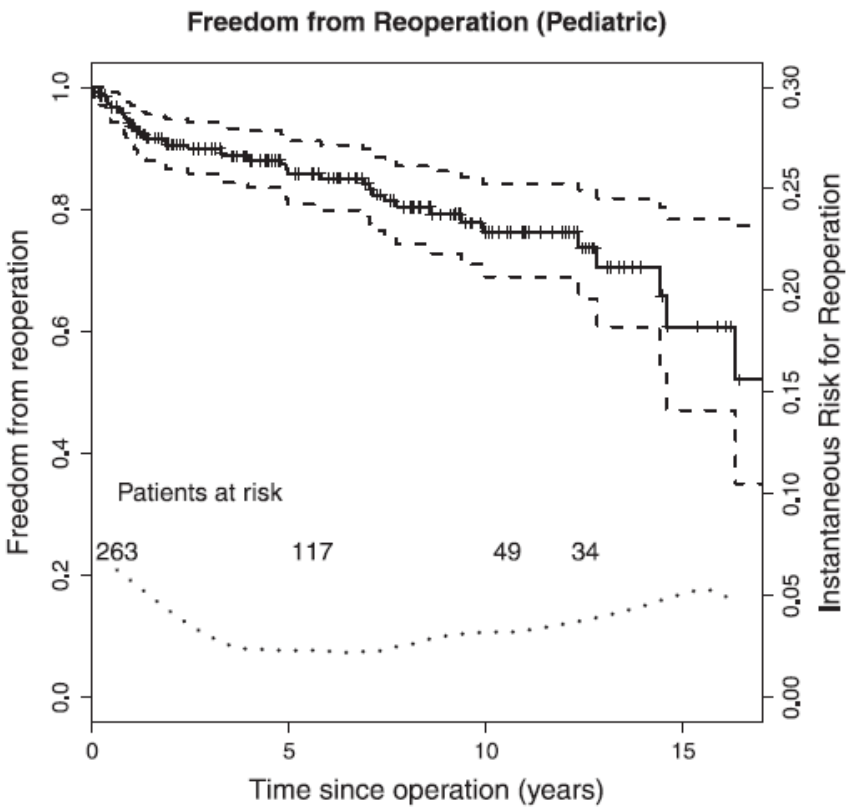

Reoperations on the pulmonary autograft and pulmonary homograft after the Ross procedure: An update on the German Dutch Ross Registry

E. Charitos, J Thorac Cardiovasc Surg 2012; 144: 813-23*

UNIVERSITÄTS-
KINDERSPITAL
ZÜRICH

Problem der defekten Herzklappen II – Non-Ross

- Ozaki-like-Aortenklappenersatz (ZAVT) – Präop Echo

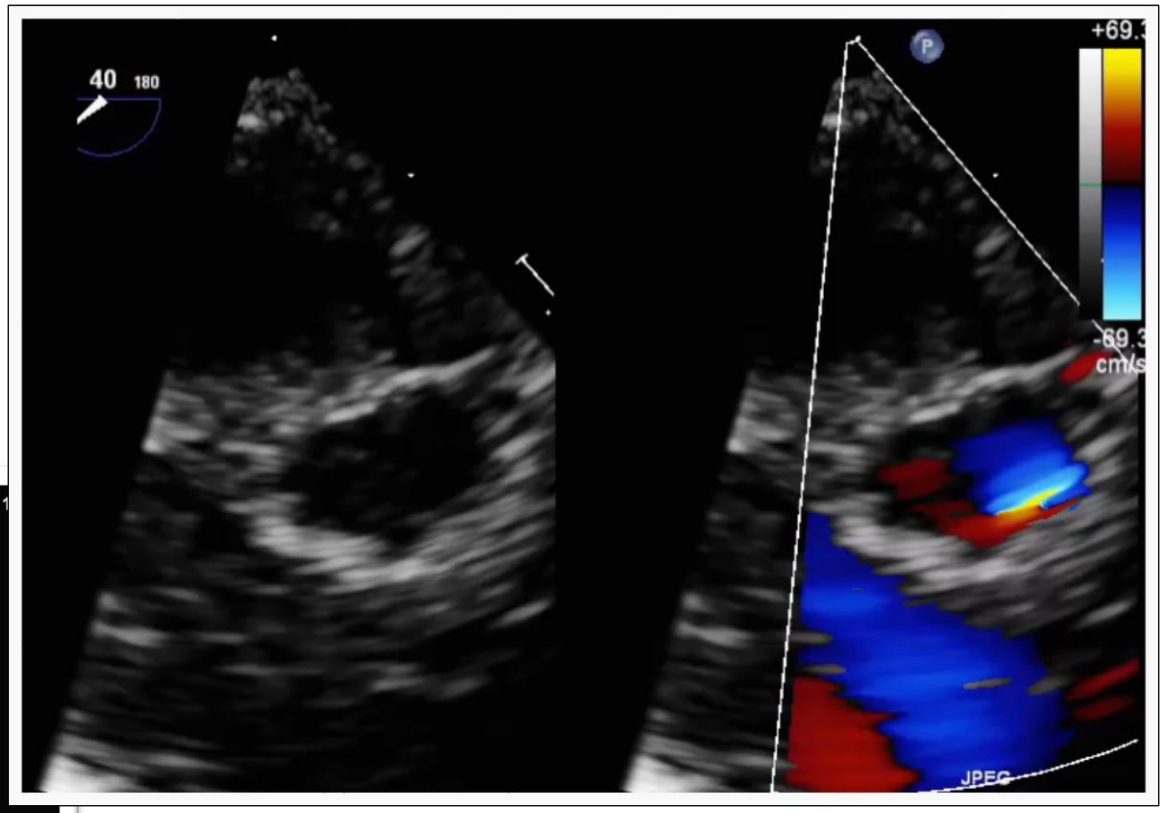

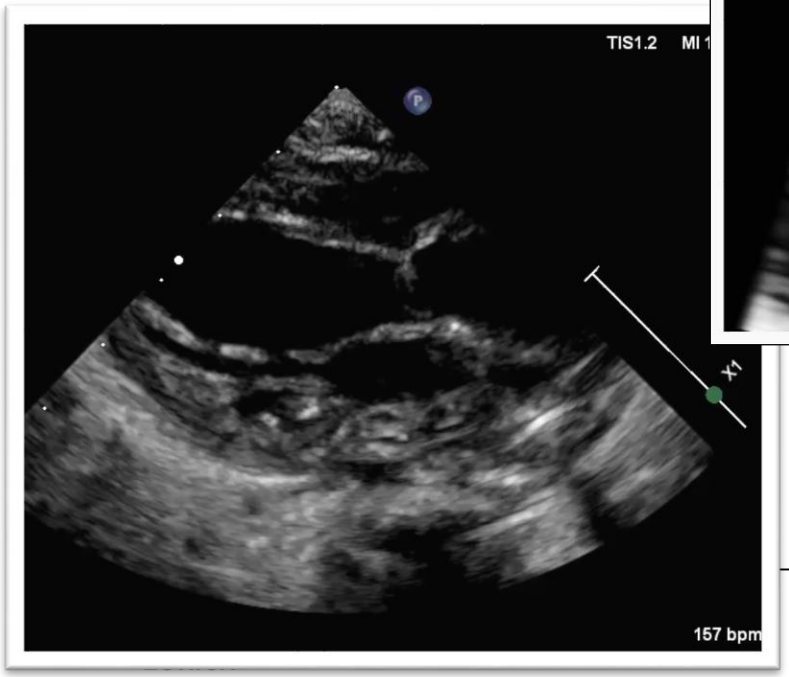

Problem der defekten Herzklappen II – Non-Ross

- ZAVT (Zürich Aortic Valvular Tube)

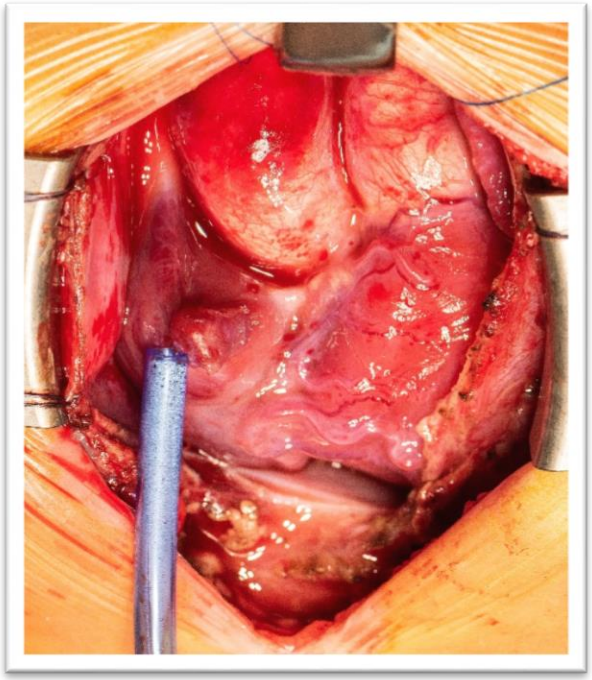

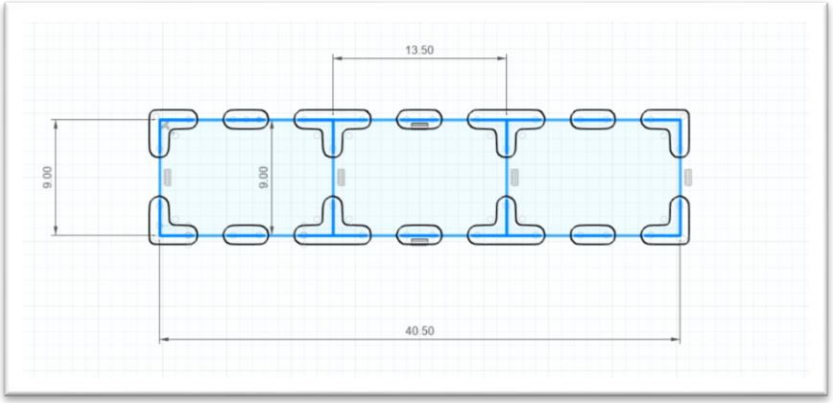

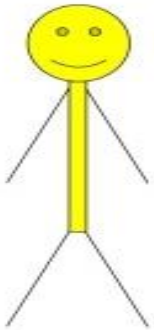

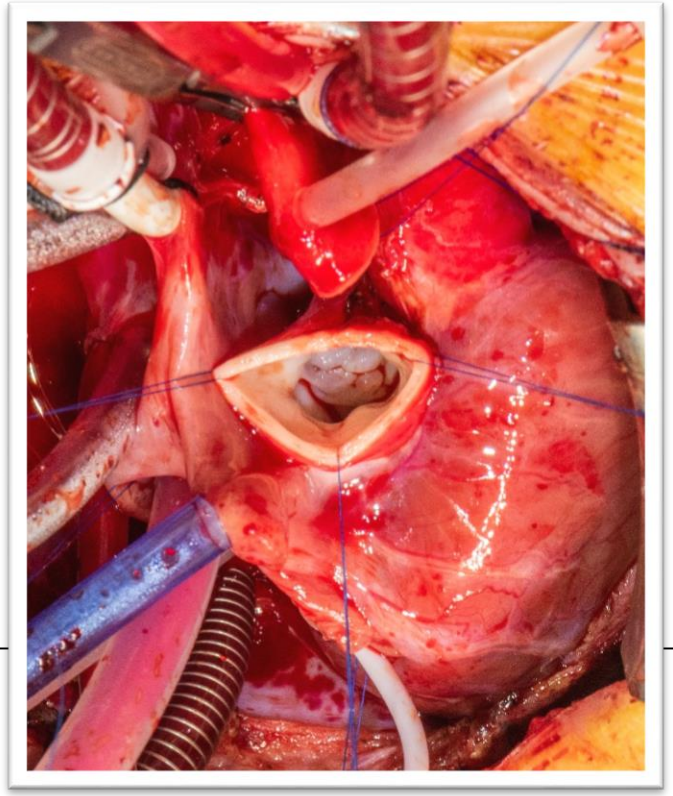

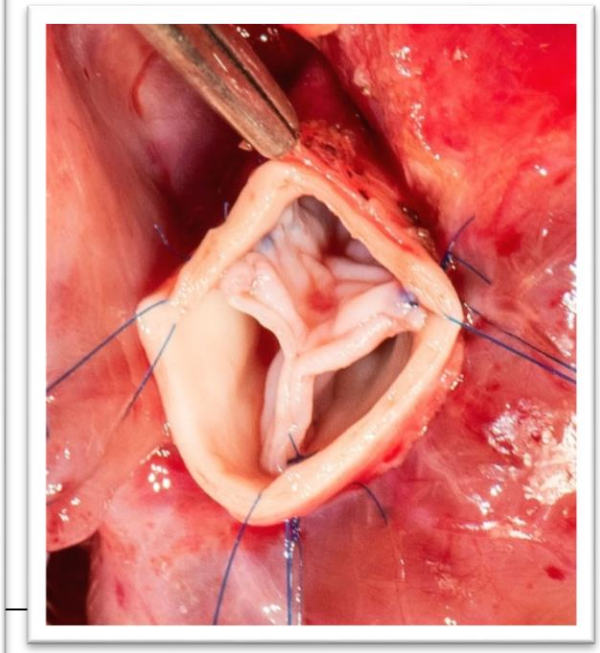

UNIVERSITÄTS-
KINDERSPITAL
ZÜRICH

Problem der defekten Herzklappen - ZAVT

- Nachuntersuchung - frühpostoperativ

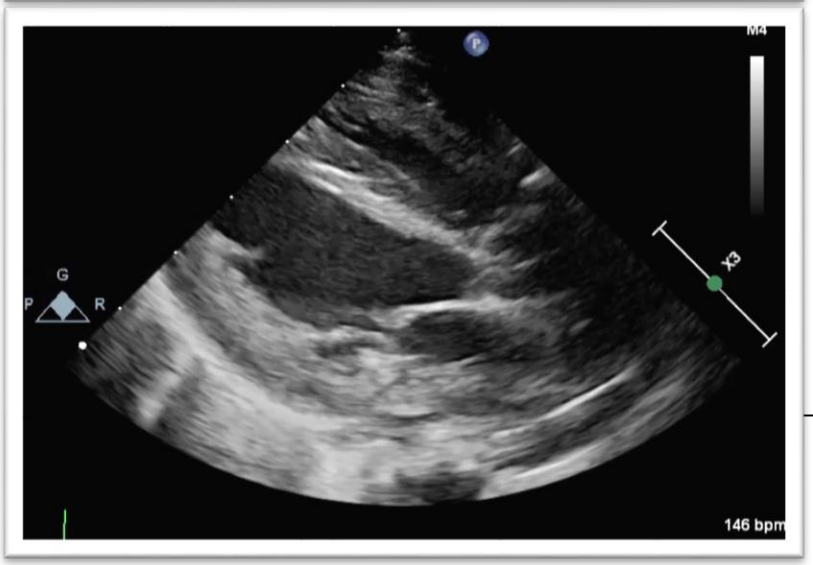

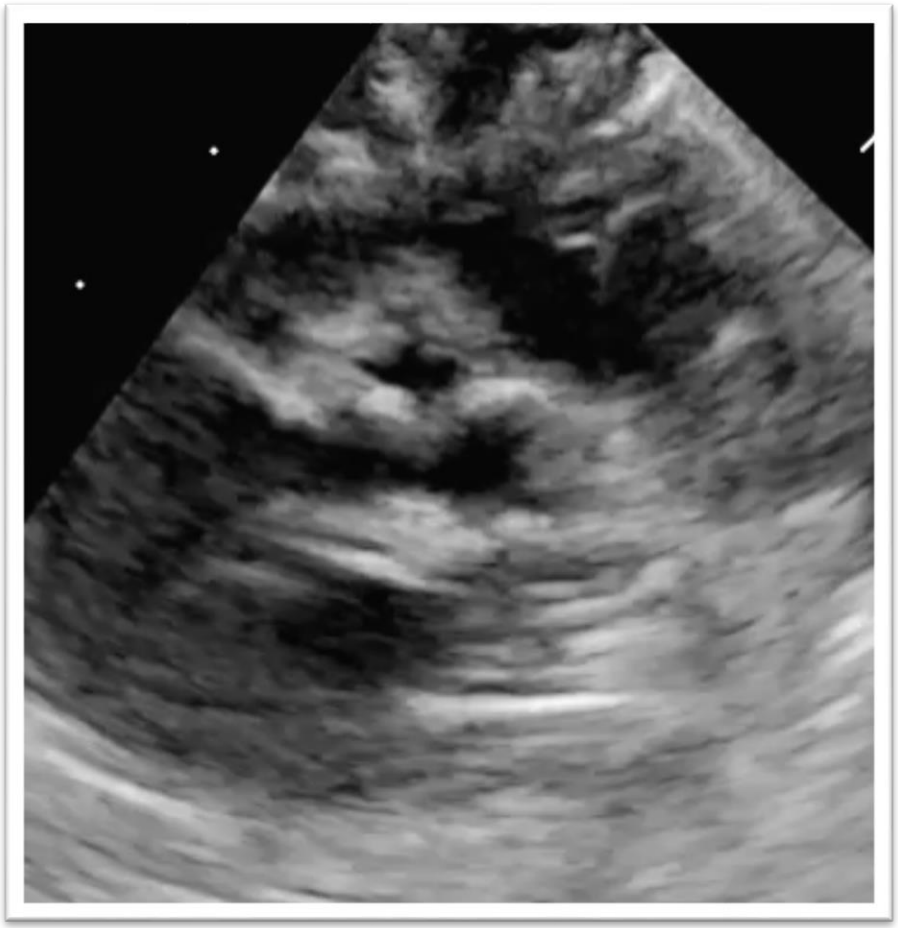

Valve-Related Events After Aortic Root Replacement With Cryopreserved Aortic Homografts

Abdullah Kaya, MD, Marc A. Schepens, MD, PhD, Wim J. Morshuis, MD, PhD, Robin H. Heijmen, MD, PhD, Aart Brutel De La Riviere, MD, PhD, and Karl M. Dossche, MD, PhD

Department of Cardiothoracic Surgery, St. Antonius Hospital Nieuwegein, Nieuwegein; and Department of Cardiothoracic Surgery, University Medical Centre Utrecht, Utrecht, the Netherlands

(Ann Thorac Surg 2005;79:1491–5)
© 2005 by The Society of Thoracic Surgeons

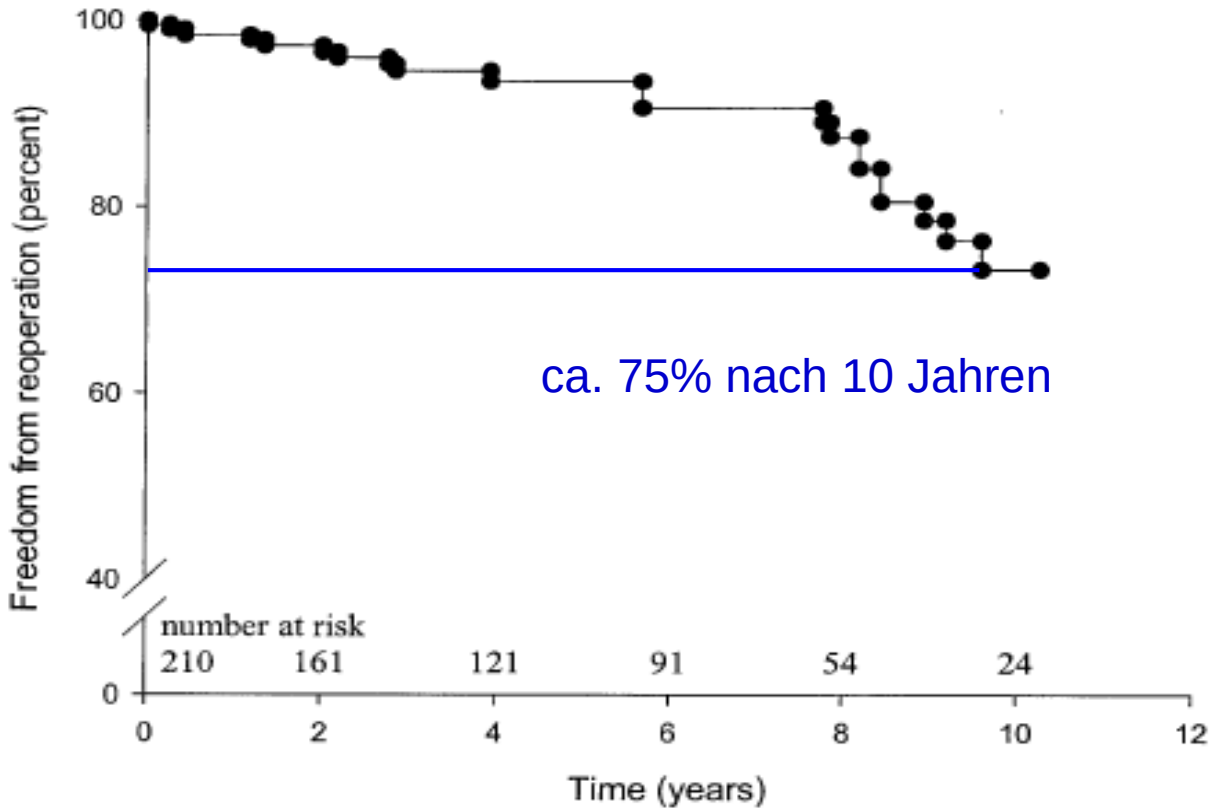

Dezellularisierte Homografts – die neue Hoffnung?

Arise®-Implantation - Fallbeispiel

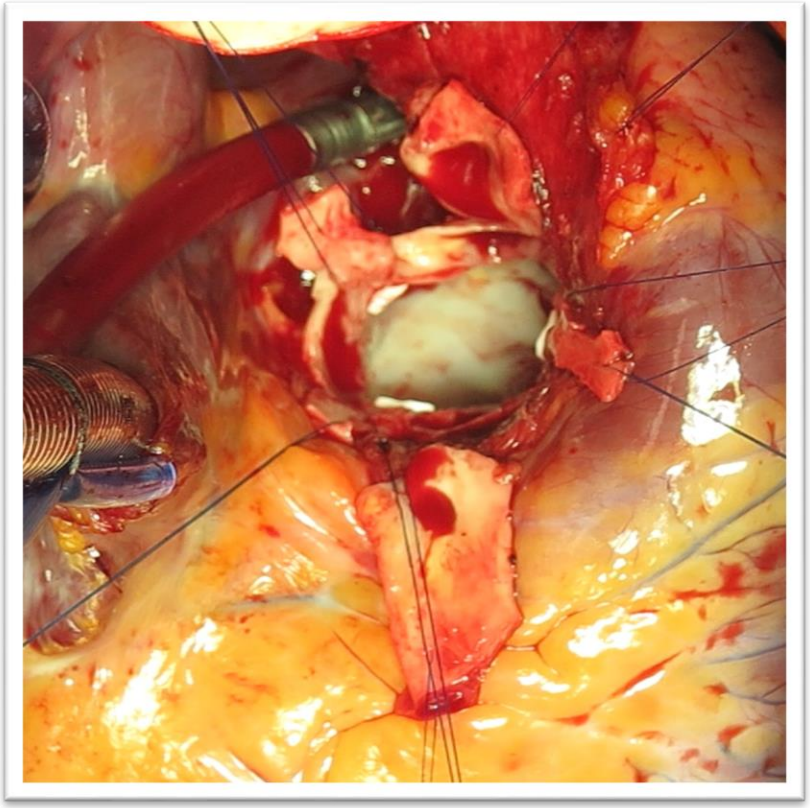

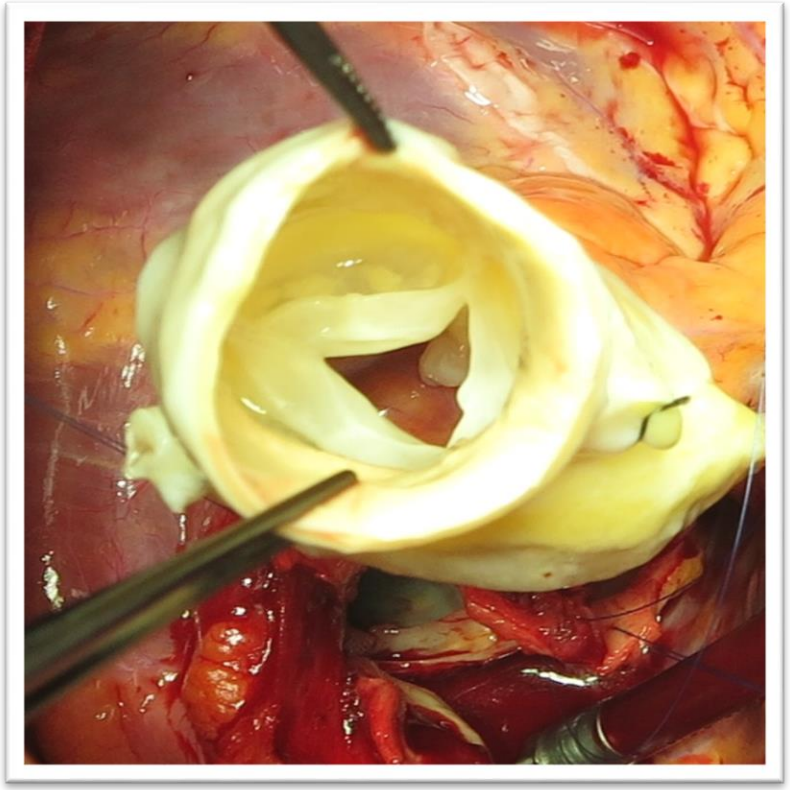

Dezellularisierte Homografts – die neue Hoffnung?

Arise®-Implantation - Fallbeispiel

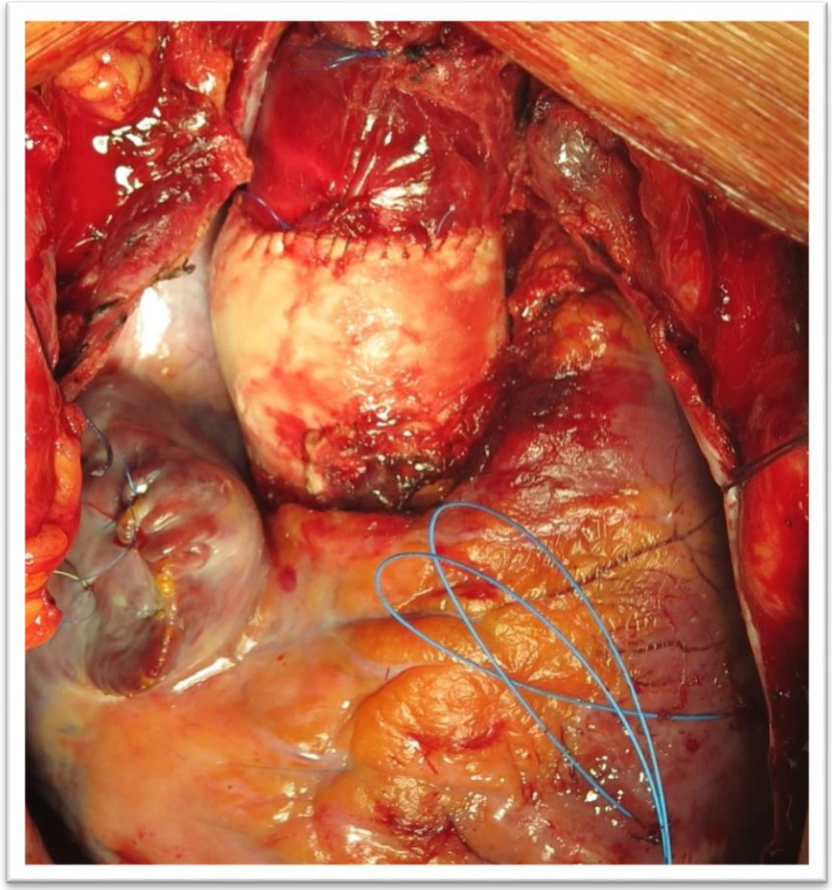

Problem der Einkammerherzen - borderliner ?

- Surgical results – Early Mortality - ECHSA

Procedure	Early mortality	Patients
Coarctation repair	1,1%	13615
Norwood	23,7%	4242
HLHC, biv. repair	10,3%	183
IAA	11,3%	1134
Truncus/IAA	10,9%	55
Aortic Arch repair	7,4%	175

Tiefer hypothermer Kreislaufstillstand (DHCA)

- deep hypothermic circulatory arrest – “Klassiche Technik“

Kühlen auf 18-20°C

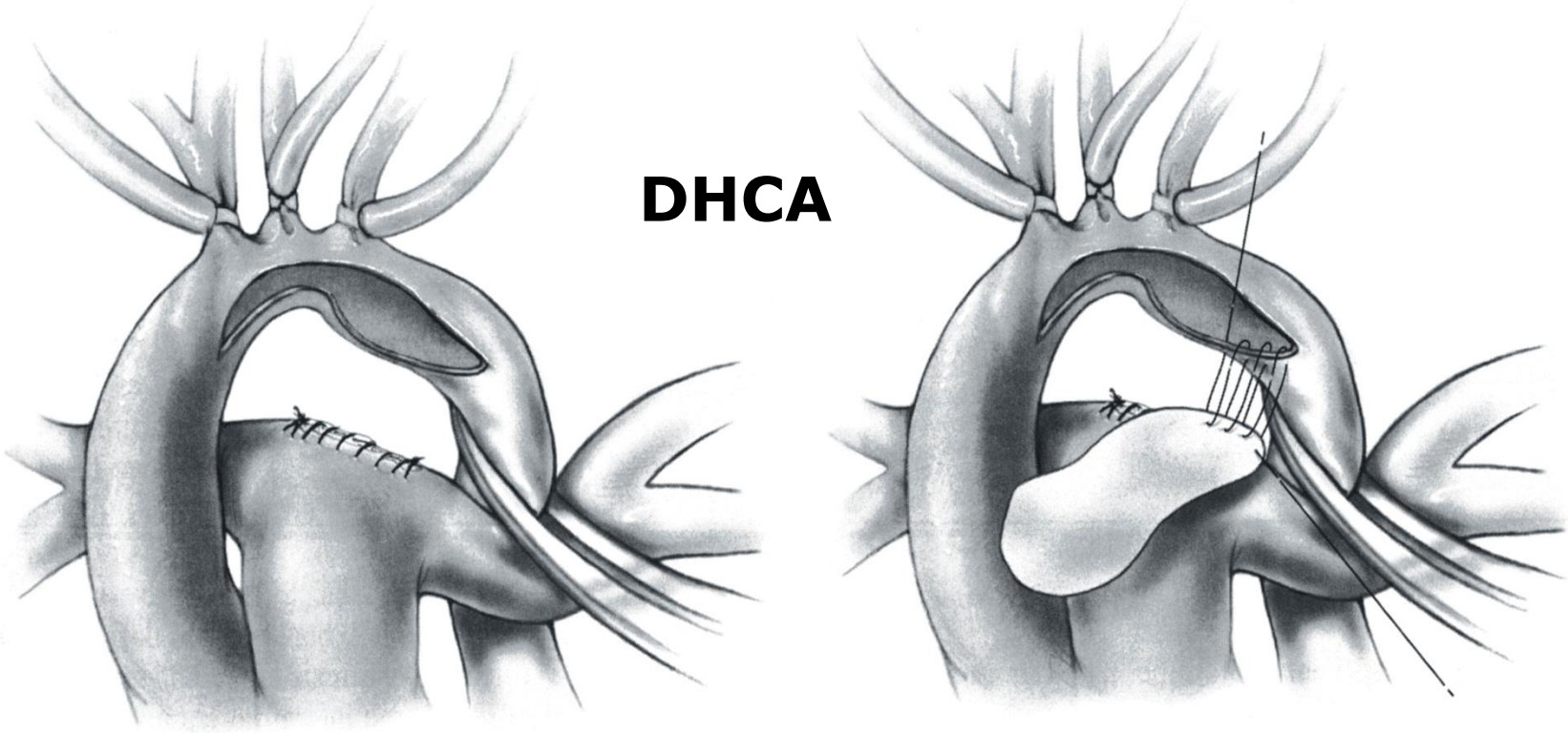

Aortenbogenkorrektur → Rewarming

Tiefer hypothermer Kreislaufstillstand (DHCA)

- deep hypothermic circulatory arrest – “Neurologie“

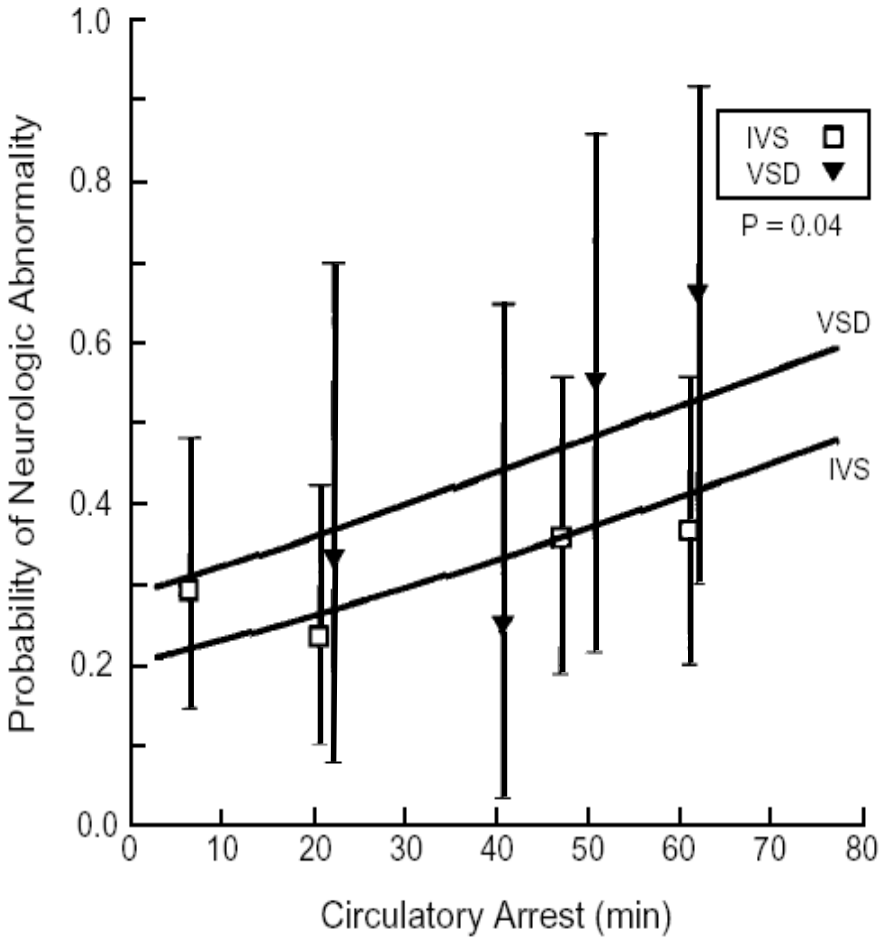

probability of neurologic damage increases with duration of DHCA

- delayed motor development
- 4 ys after surgery still present

Bellinger et al. Developmental and neurological status of children after heart surgery with hypothermic circulatory arrest or low-flow cardiopulmonary bypass.
New Engl J Med. 1995 Mar 2, Vol. 332 (9): 549-55

UNIVERSITÄTS-
KINDERSPITAL
ZÜRICH

aktuelle Techniken – “global perfusion!“

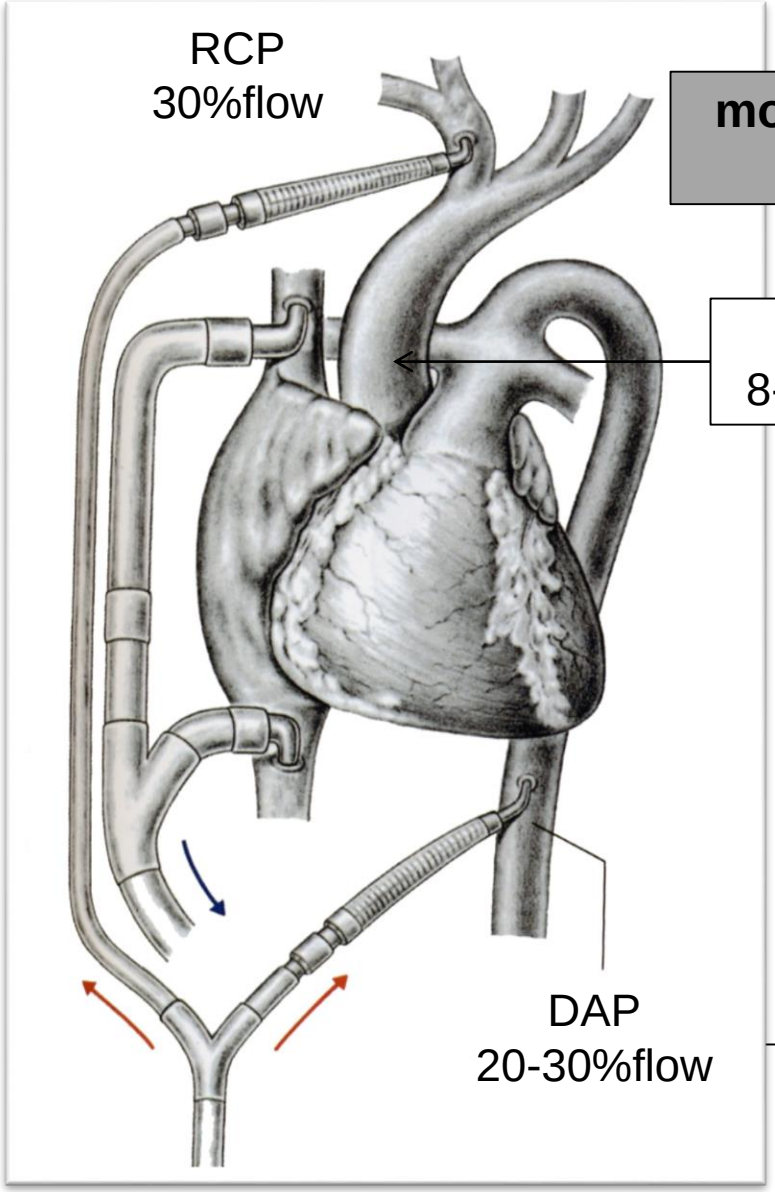

moderate Hypothermie
28°C

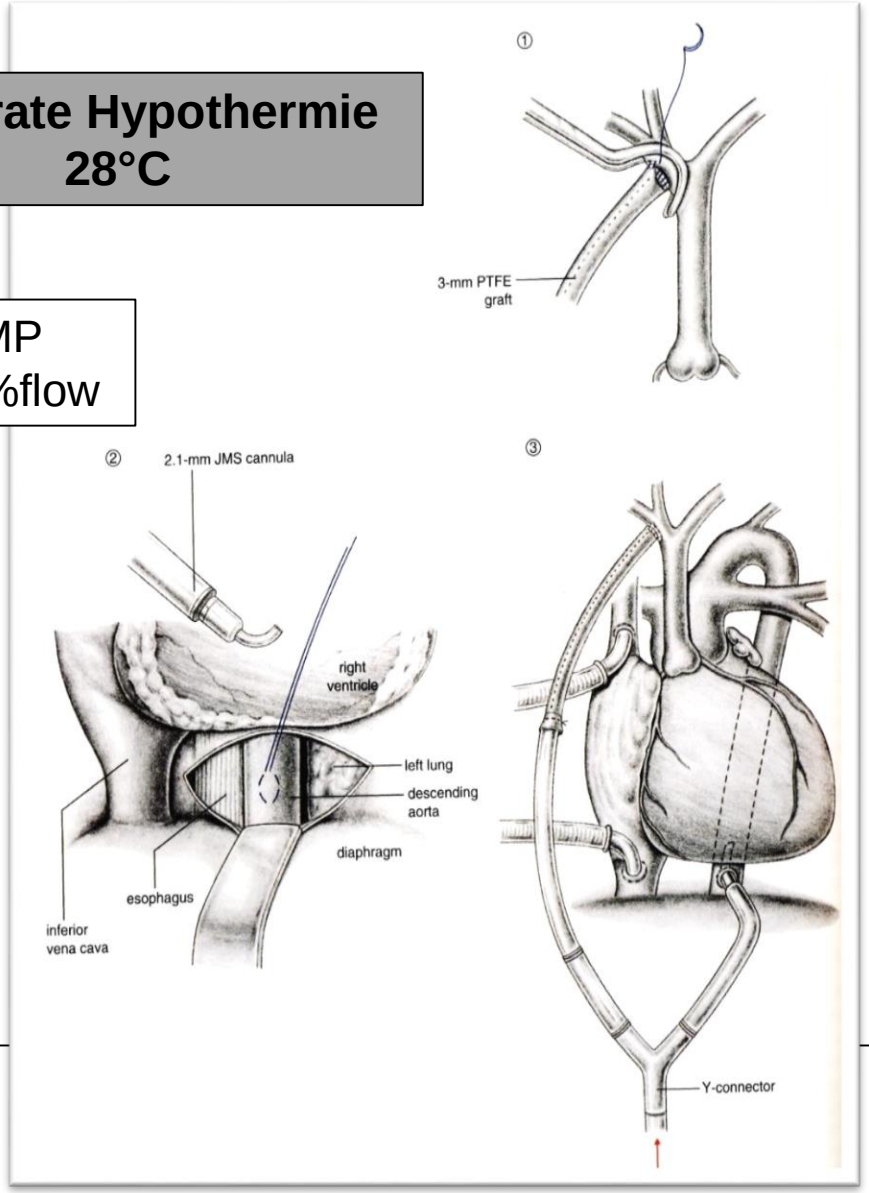

aktuelle Techniken – “global perfusion!“

- Monitoring

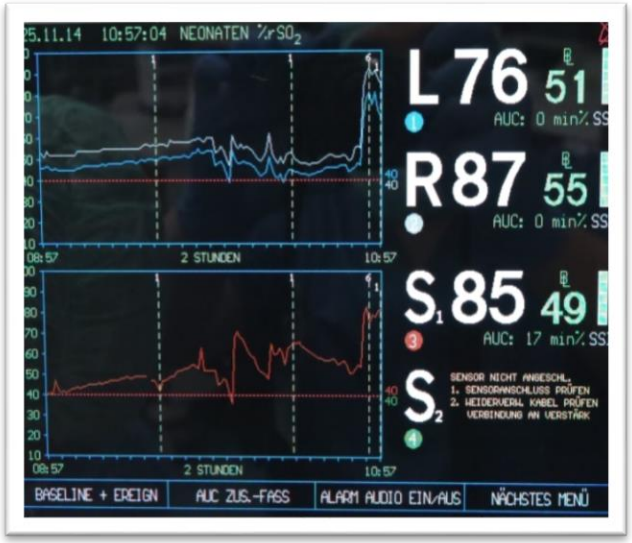

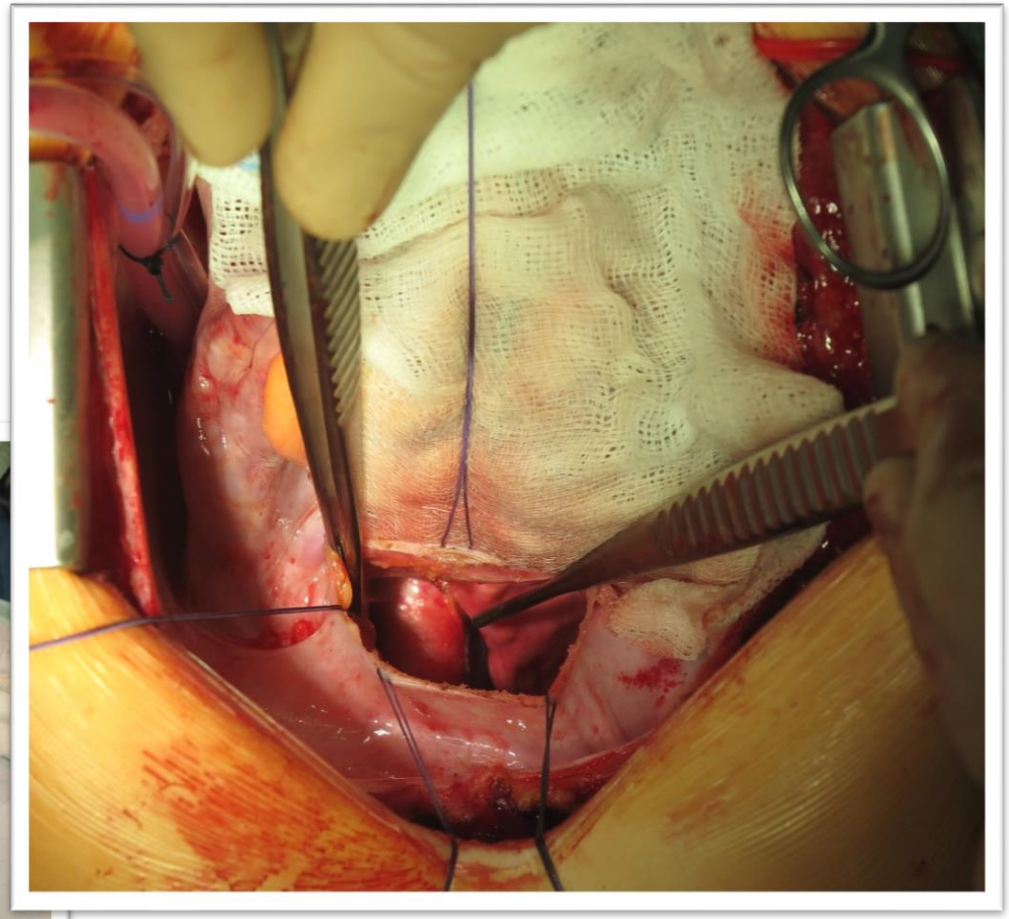

Norwood-I-palliation – beating heart

- “total body perfusion“

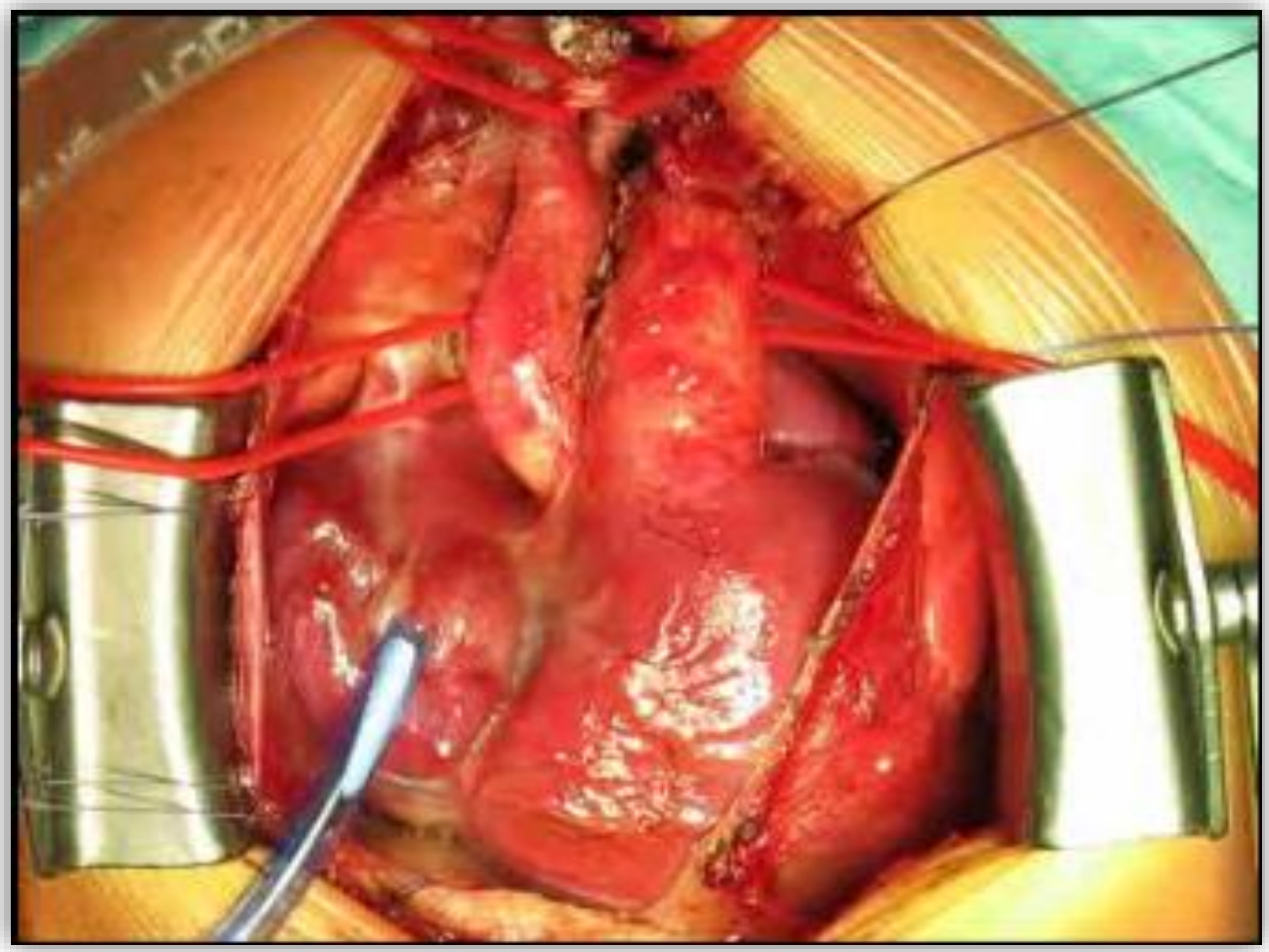

Norwood: „total body perfusion“

- postoperatives Ergebnis - Herzkatheter

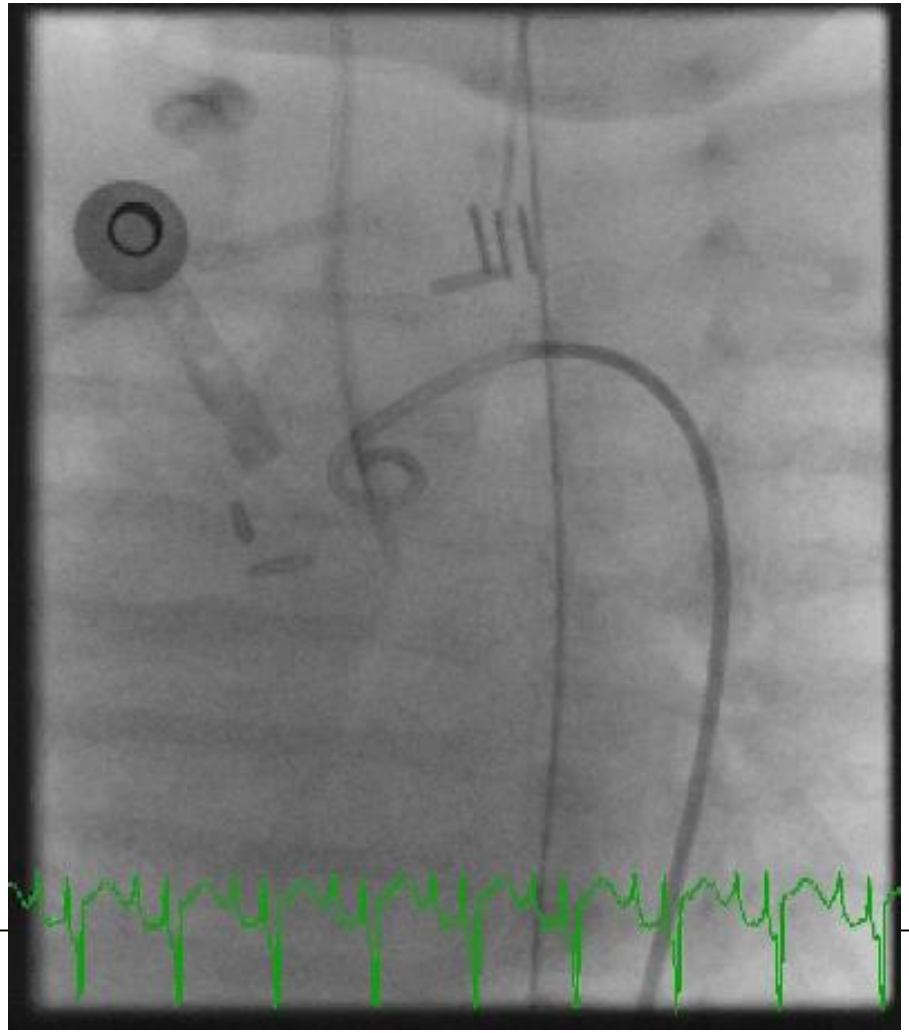

Surgical results – Early Mortality - ECHSA

Procedure	early mortality	patients	Erlangen	early mortality
Coarctation repair	1,1%	13615	208	0,6%
Norwood	23,7%	4242	81	17,3%
HLHC, biv. repair	10,3%	183	14	7,1%
IAA	11,3%	1134	17	5,8%
Truncus/IAA	10,9%	55	5	0,0%
Aortic arch repair	7,4%	175	79	0,0%

Problem der Einkammerherzen - Fontankreislauf

- fehlender subpulmonaler Ventrikel !

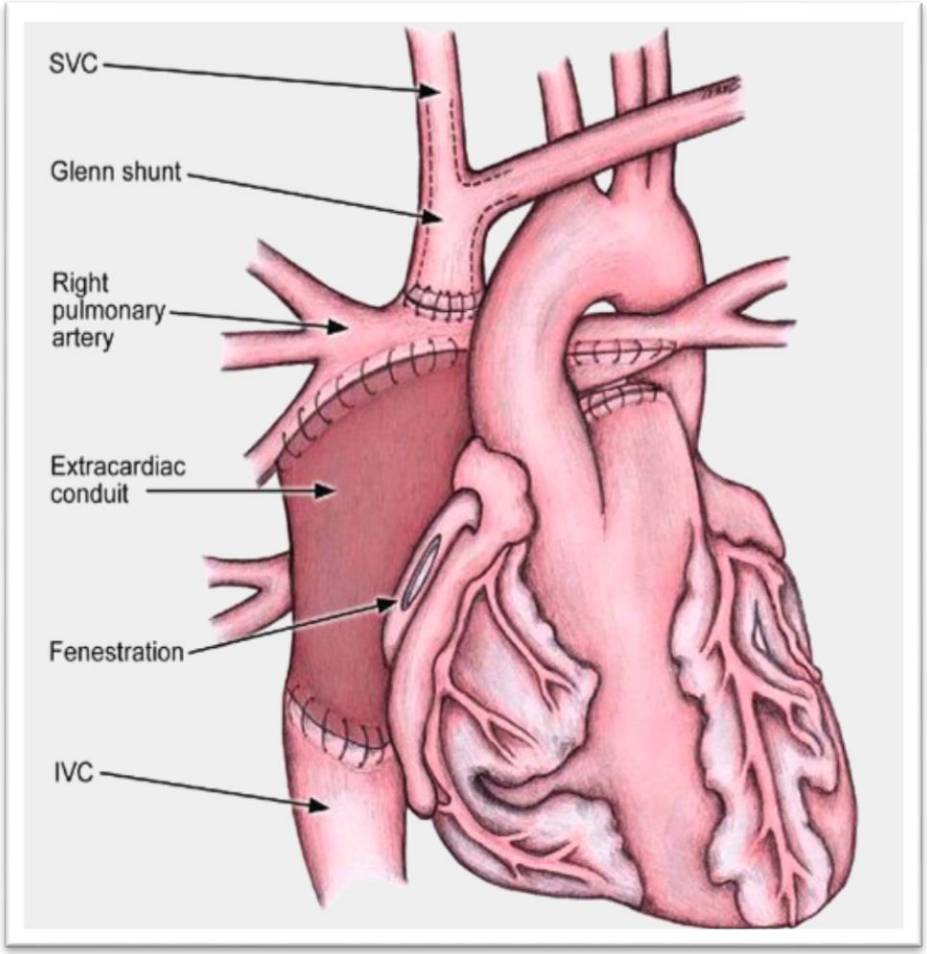

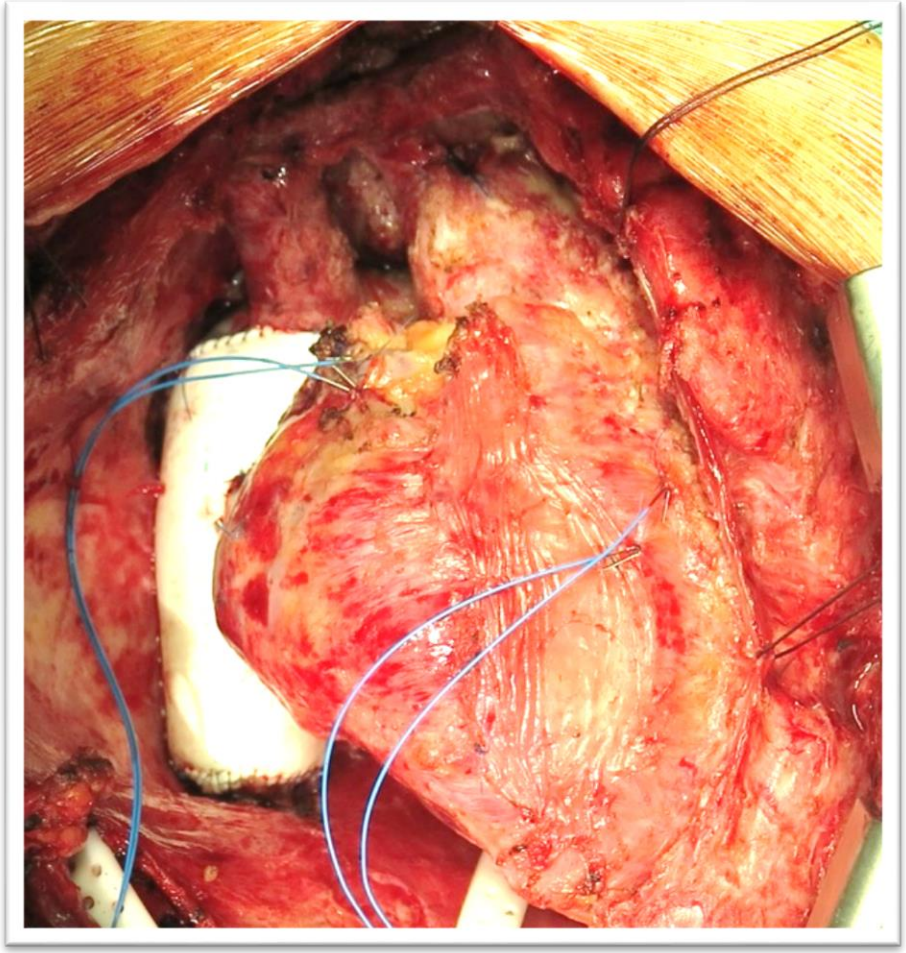

Problem der Einkammerherzen - Fontankreislauf

- fehlender subpulmonaler Ventrikel !

- Low cardiac output (akut und chronisch)
- Pleuraergüsse (akut und chronisch)
- Arrhythmien (Nahtreihen am Vorhof)
- Protein losing enteropathy (PLE) → Immundefizienz
- Hepatische Dysfunktion (Gerinnung …)
- arteriovenöse Malformationen (AVM) in beiden Lungen
- Progressive Zyanose
- chronische Belastungsintoleranz (Dyspnoe/Oedeme)
- Plastische Bronchitis

Problem der Einkammerherzen - Fontankreislauf

- fehlender subpulmonaler Ventrikel !

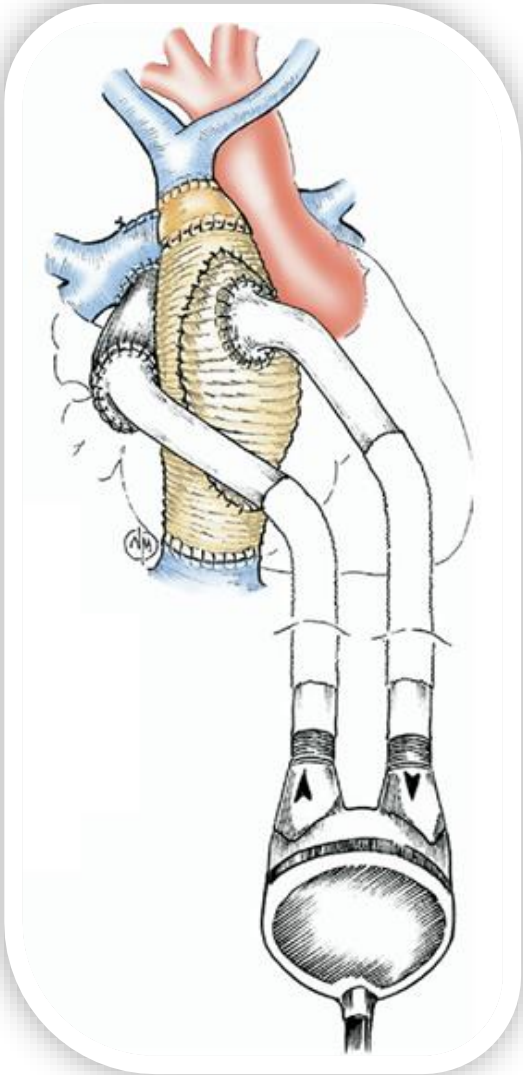

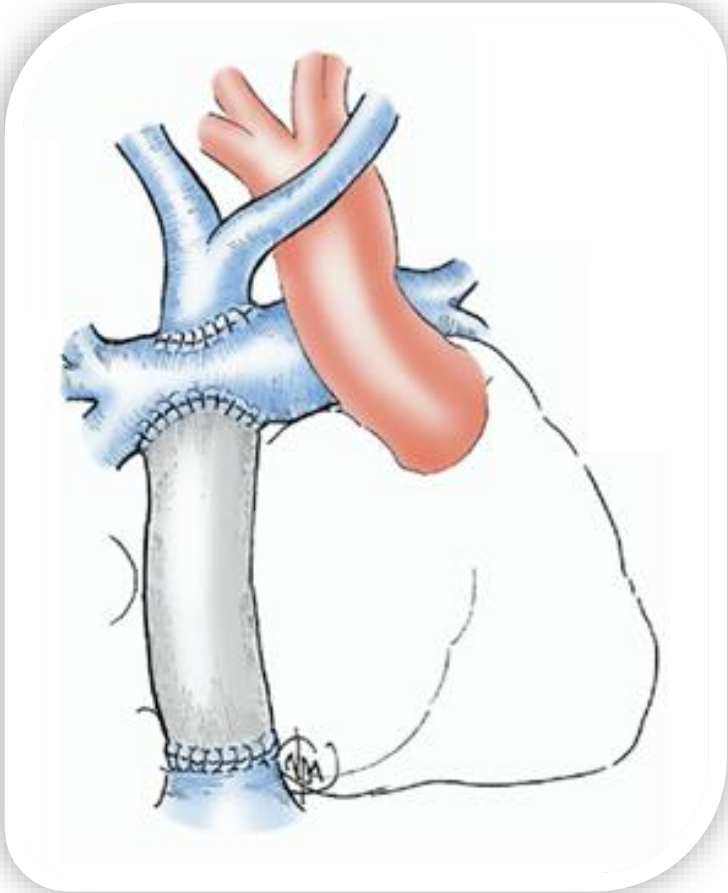

→ finale Lösung – HTX (Herztransplantation)

Kinderherzchirurgische Abteilung (UK-ER)

- Behandlungserfolge (n=3939 Operationen/Stand 2021 ER)
- Kinderspital Zürich (n=256 Operationen/2021 und 2022)

Vitium	Letalität 1. Lebensjahr	OP-Risiko Europa	OP-Risiko Erlangen	OP-Risiko KiSpi
Ventrikelseptumdefekt (VSD)	20-30%	0,7 %	0.5%	0.0%
Vorhofseptumdefekt (ASD)	0,6%	0,3 %	0,4%	0,0%
Aortenisthmusstenose (ISTA)	15%	2,2 %	0,6%	0,0%
Persistierender Ductus Botalli (PDA)	20%	2,1 %	0,0% *	0.0%
TGA	90%	5,6 % - 9,4%	2,0%	0,0%
Fallot-Tetralogie	30%	2,3 %	1,2%	0,0%
Totale Lungenvenenfehlmündung	80%	9,8 %	5,4%	0,0%
Kompletter AV-Kanal (CAVSD)	bis 80%	4,9 %	0,9%	0,0%
Univentrikuläres Herz (UVH)	50-60%	5-25%	4,9%*	7,3%*
Hypoplastisches Linksherzsyndrom	100%	23,6 %	17,3%	0,0%
Truncus arteriosus communis	80-90%	15,8%	3,4%	0,0%

UNIVERSITÄTS-
KINDERSPITAL
ZÜRICH

Operationsergebnisse - Quality of Care 2008-2019

- ECHSA-Database

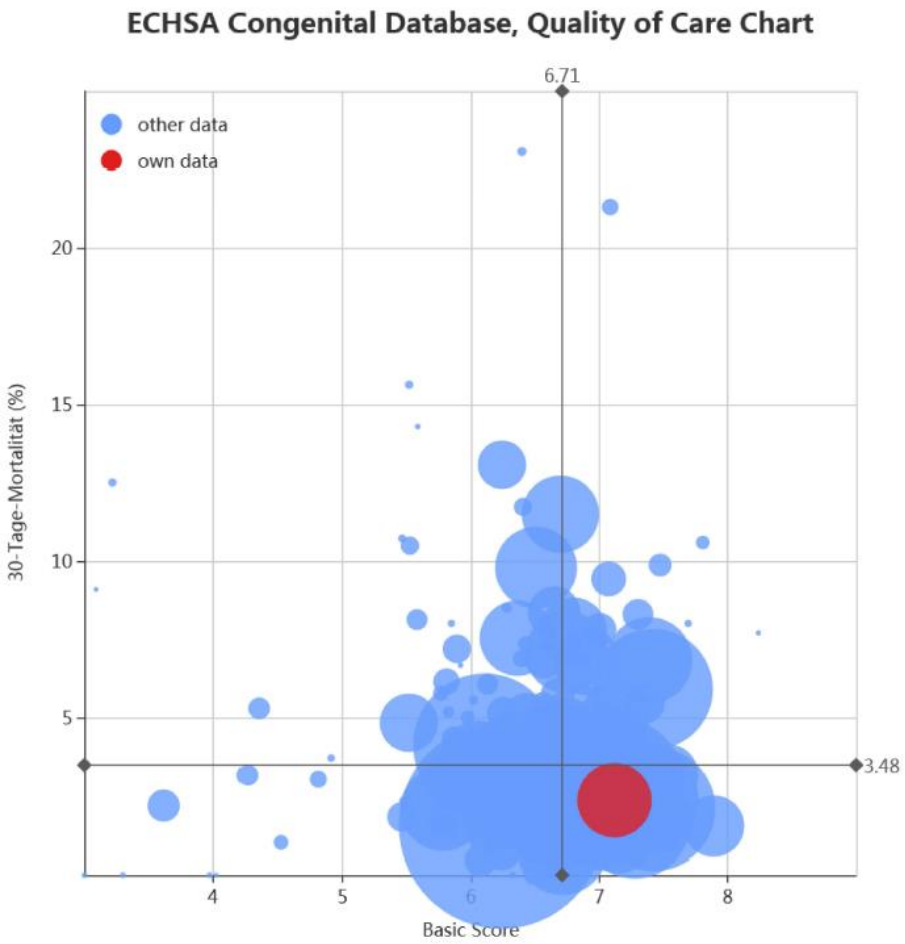

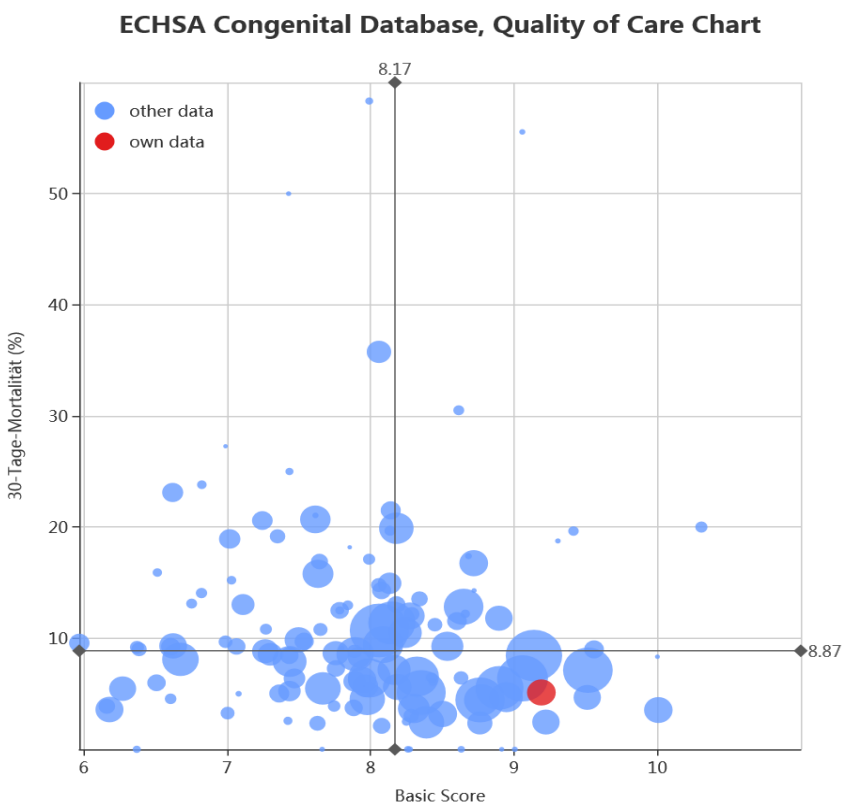

Take home messages

- **Operationsergebnisse**
  - Über 90% der operierten Kinder erreichen das Erwachsenenalter
- **Möglichkeiten**
  - Weniger invasive Techniken
  - Organerhaltende Perfusion
- **Grenzen**
  - Mortalität und Morbidität immer noch vorhanden
  - Lebenslange Palliationen (wie z.B. Fontanzirkulation) werden weiterhin nötig sein
  - Transplantation und spätere biventrikuläre Korrekturen für Patienten mit einer Einkammerzirkulation bleiben limitiert

Vielen Dank und einen schönen Advent!